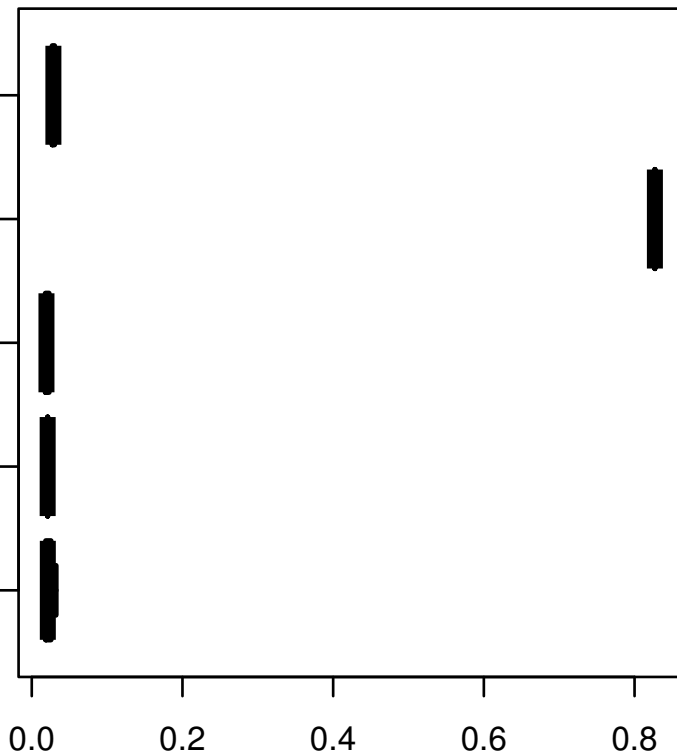


MAP4K4

HISTOLOGICAL
TYPE
MUCINOUS
ADENOCARCINOMA
OF
ENDOCERVICAL
ENDOMETRIAL
ADENOCARCINOMA
OF ENDOCERVIX
ENDOCERVICAL
TYPE OF
ADENOCARCINOMA
ENDOCERVICAL
ADENOCARCINOMA
OF THE USUAL
TYPE
CERVICAL
SQUAMOUS CELL
CARCINOMA



ANOVA-P = $2.35e-60$

log2-EXPR