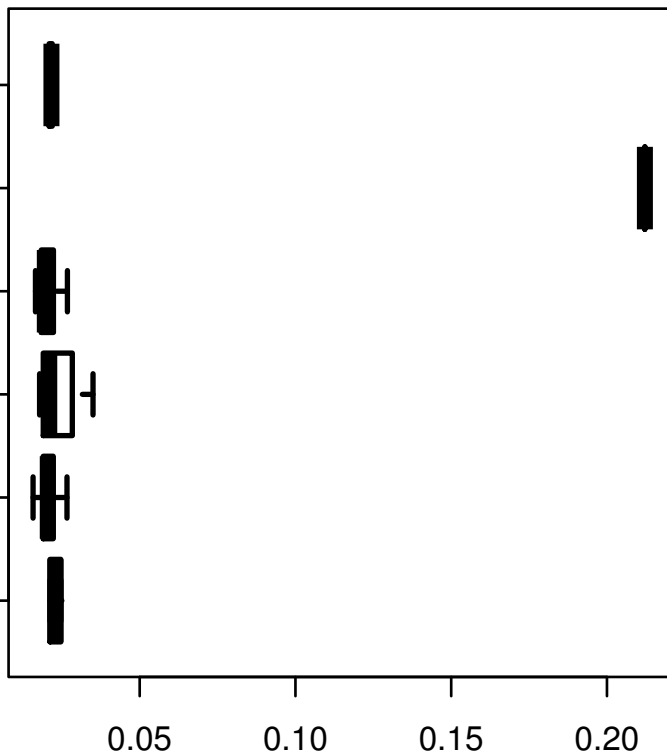


# SETD7

HISTOLOGICAL  
TYPE  
MUCINOUS  
ADENOCARCINOMA  
OF  
ENDOCERVICAL  
ENDOMETRIAL  
TYPE  
ADENOCARCINOMA  
OF ENDOCERVIX  
ENDOCERVICAL  
TYPE OF  
ADENOCARCINOMA  
ENDOCERVICAL  
ADENOCARCINOMA  
OF THE USUAL  
CERVICAL  
TYPE  
SQUAMOUS CELL  
CARCINOMA  
ADENOSQUAMOUS



ANOVA-P =  $1.58e-107$  log2-EXPR