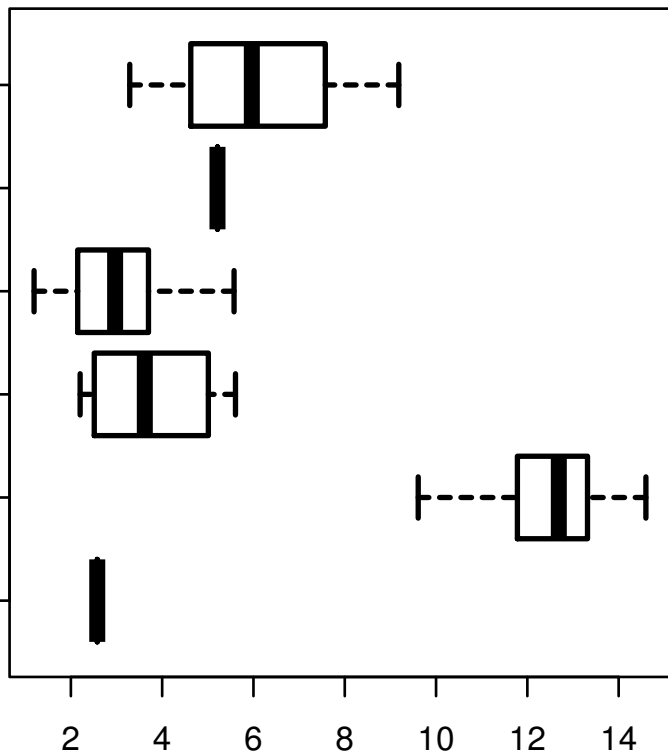


TP63|8626

HISTOLOGICAL
TYPE
MUCINOUS
ADENOCARCINOMA
OF
ENDOCERVICAL
ENDOMETRIUM
ADENOCARCINOMA
OF ENDOCERVIX
ENDOCERVICAL
TYPE OF
ADENOCARCINOMA
ENDOCERVICAL
ADENOCARCINOMA
OF THE USUAL
CERVICAL
TYPE
SQUAMOUS CELL
CARCINOMA
ADENOSQUAMOUS



ANOVA-P = 1.76e-36

log2-EXPR