

# HSA-MIR-21

HISTOLOGICAL

TYPE

MUCINOUS

LUNG (SOLID)

CARCINOMA

PREDOMINANT

RING

ADENOCARCINOMA

ADENOCARCINOMA

ADENOCARCINOMA

ADENOCARCINOMA

ADENOCARCINOMA

ADENOCARCINOMA

ADENOCARCINOMA

ADENOCARCINOMA

ADENOCARCINOMA

ADENOCARCINOMA

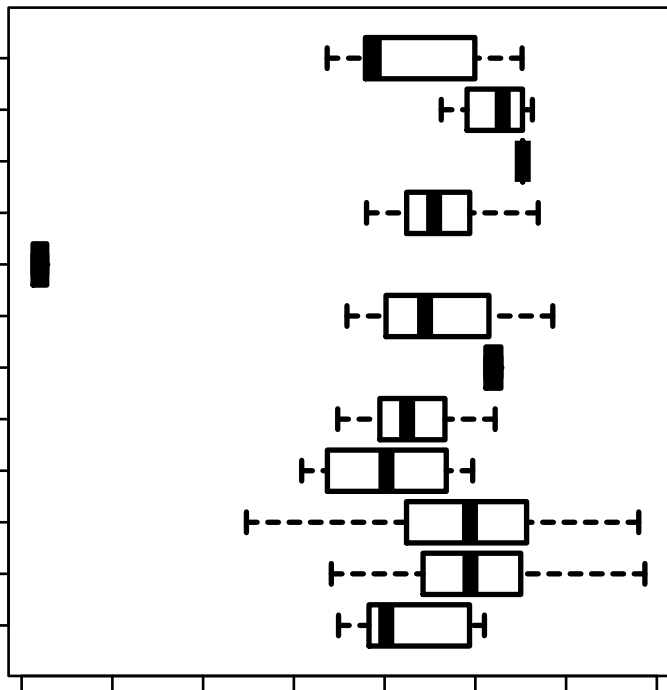
ADENOCARCINOMA

ADENOCARCINOMA

ADENOCARCINOMA

ADENOCARCINOMA

ADENOCARCINOMA



16.0

17.0

18.0

19.0

log2-EXPR

ANOVA-P = 2.79e-08