

HSA-MIR-21

HISTOLOGICAL

TYPE

THYROID

PAPILLARY

CARCINOMA -

TALL CELL (>=

50% TALL CELL

PAPILLARY

FEATURES)

CARCINOMA -

FOLLICULAR

(>= 99%

FOLLICULAR

THYROID

PATTERNED)

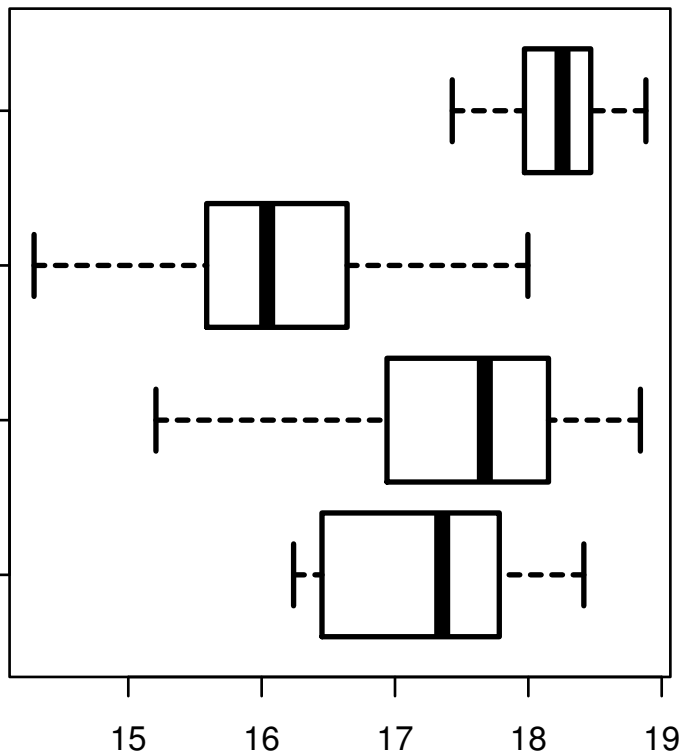
PAPILLARY

CARCINOMA -

CLASSICAL/USUAL

OTHER

SPECIFY



log2-EXPR

ANOVA-P = 9.66e-41