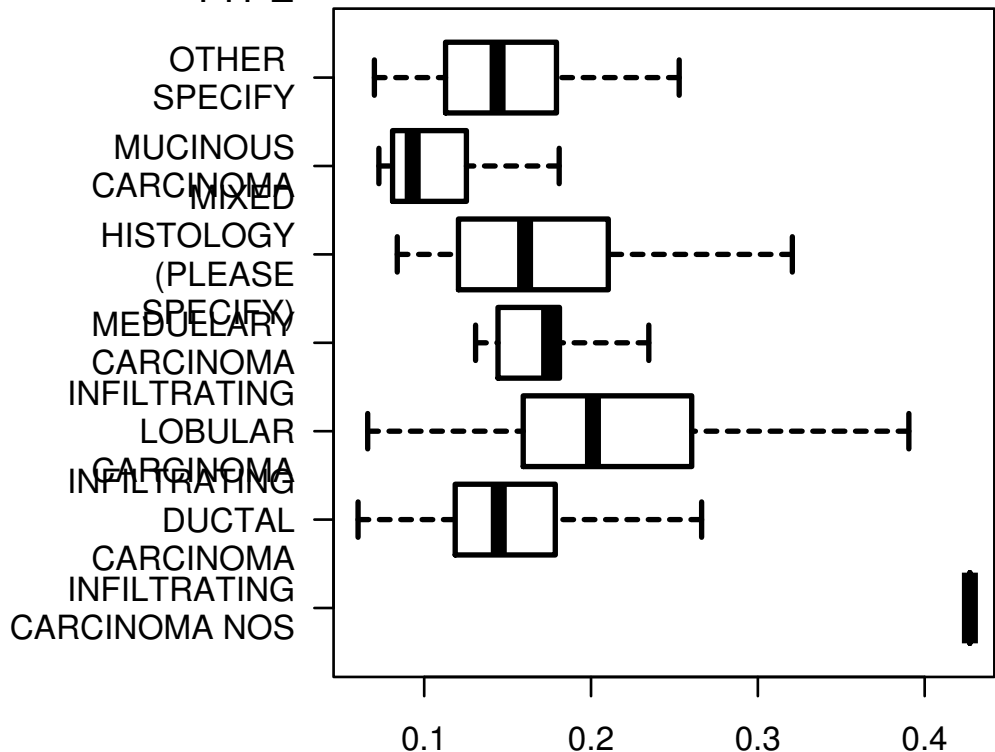


HISTOLOGICAL  
TYPE

ACOT7



log2-EXPR  
Kruskal-Wallis P = 2.47e-16