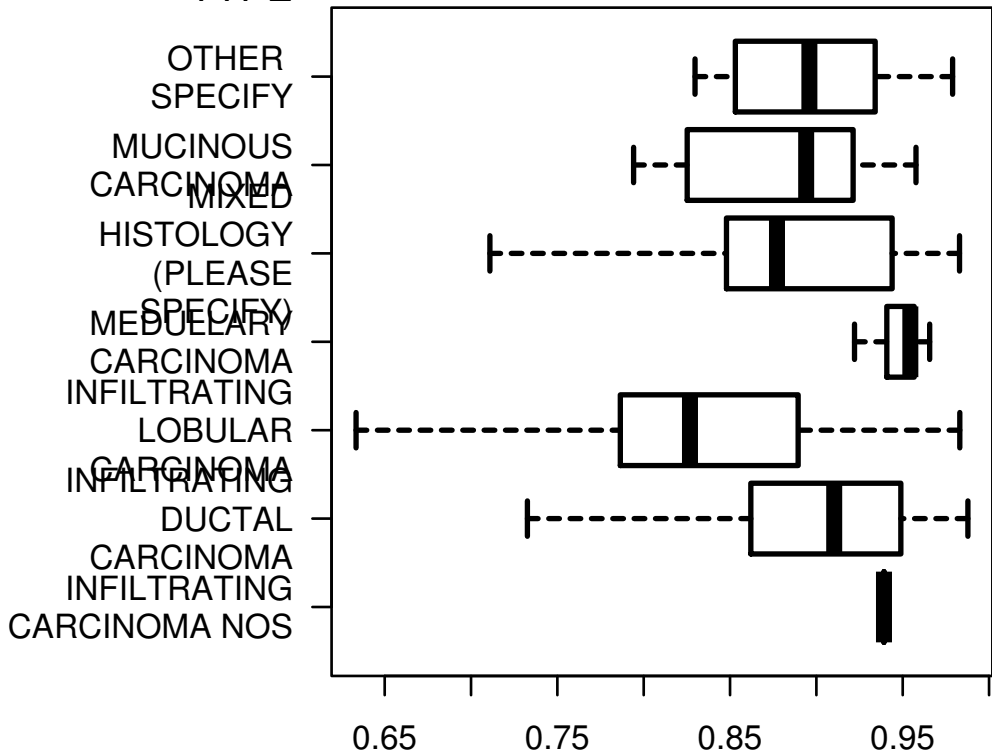


HISTOLOGICAL
TYPE

PRCD



log2-EXPR
Kruskal-Wallis P = 8.11e-18