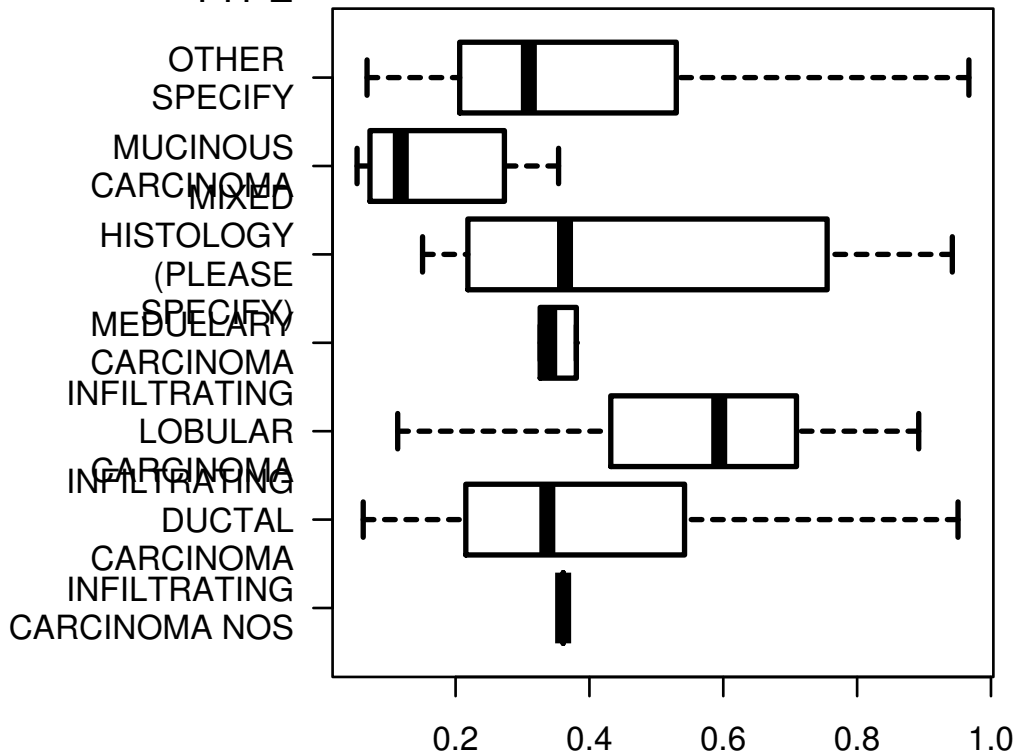


HISTOLOGICAL  
TYPE

PELO\_1



log2-EXPR  
Kruskal-Wallis P = 6.38e-17