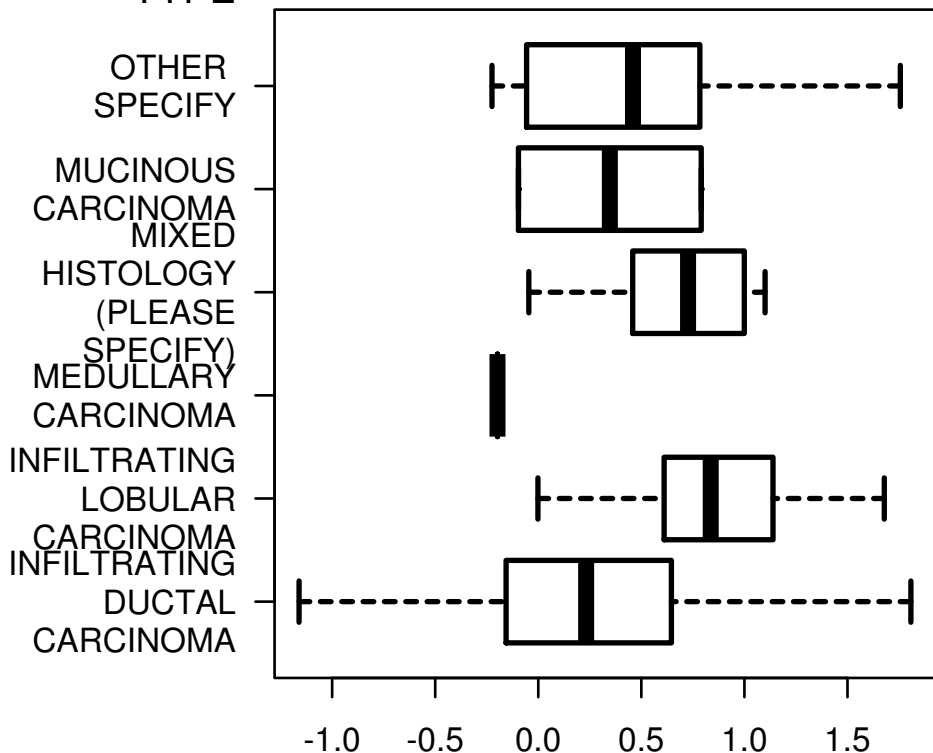


HISTOLOGICAL
TYPE

GLTSCR2



log2-EXPR
Kruskal-Wallis P = 3.98e-10