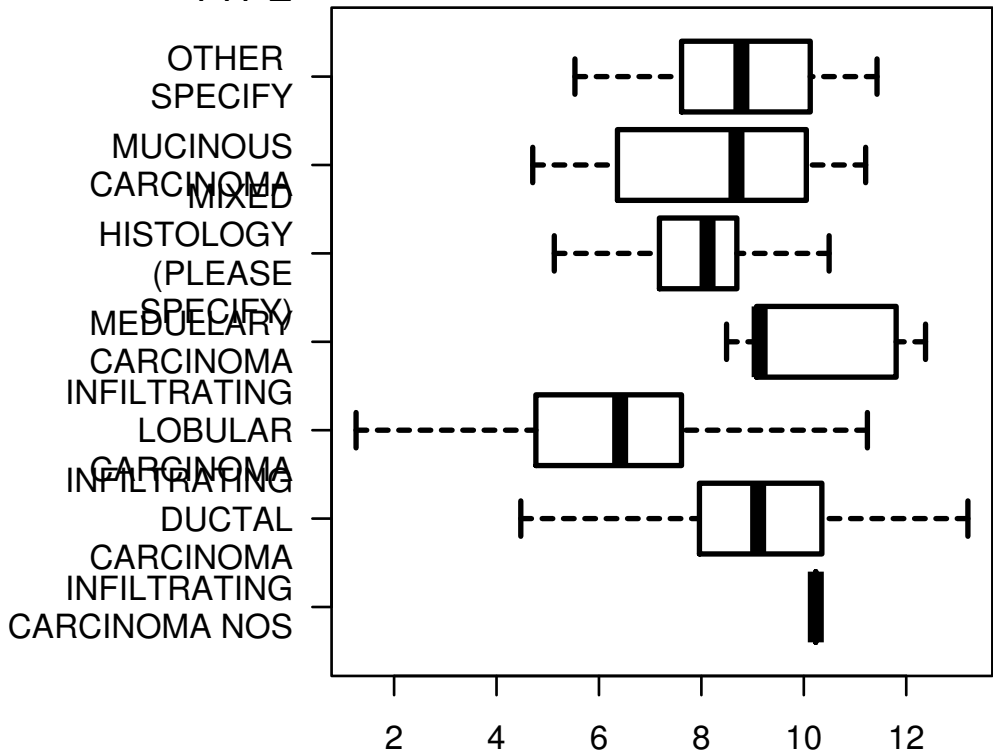


HISTOLOGICAL
TYPE

HSA-MIR-210



log2-EXPR
Kruskal-Wallis P = 1.18e-40