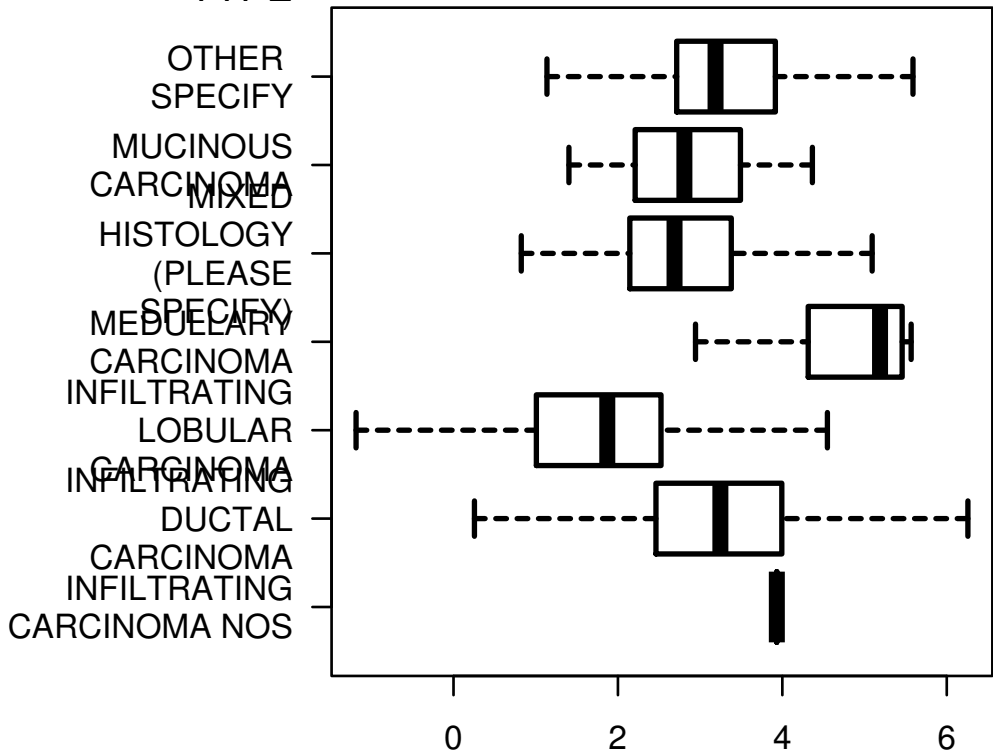


HISTOLOGICAL  
TYPE

# HSA-MIR-1306



log2-EXPR

Kruskal-Wallis P = 1.24e-33