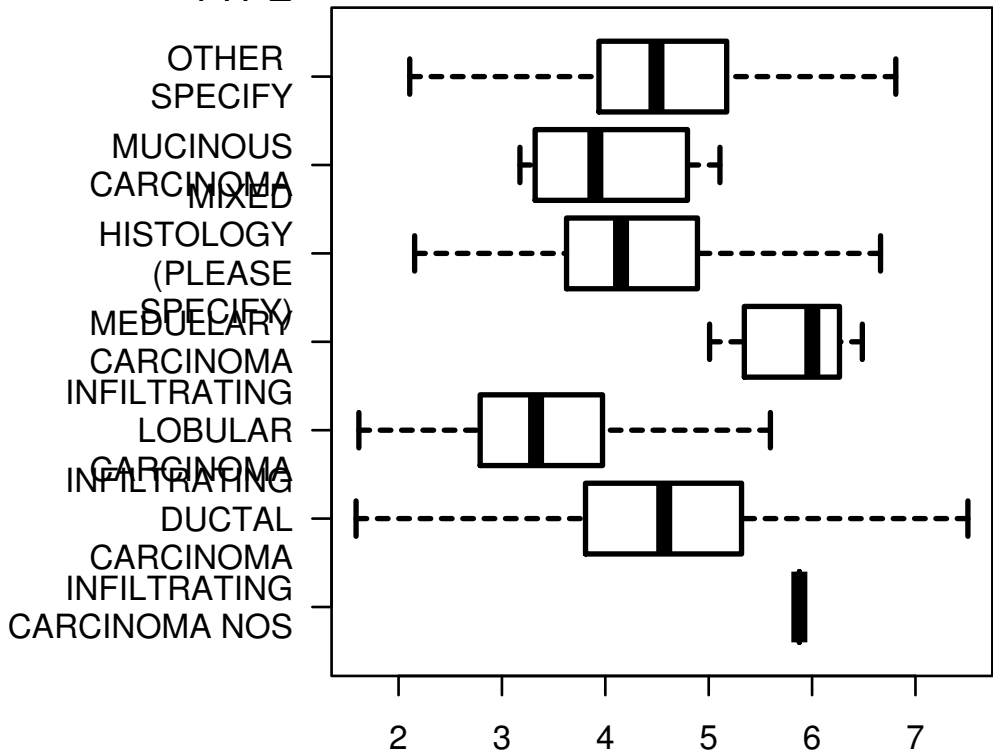


HISTOLOGICAL  
TYPE

# HSA-MIR-130B



log2-EXPR  
Kruskal-Wallis P = 6.44e-33