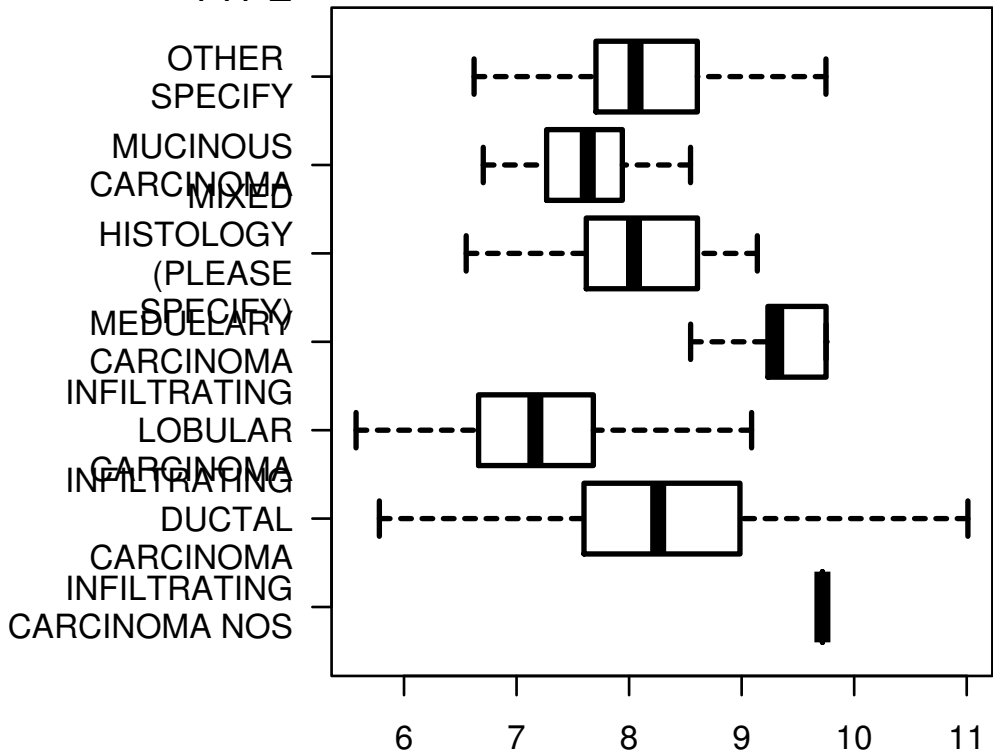


HISTOLOGICAL
TYPE

HSA-MIR-197



log2-EXPR
Kruskal-Wallis P = 7e-32