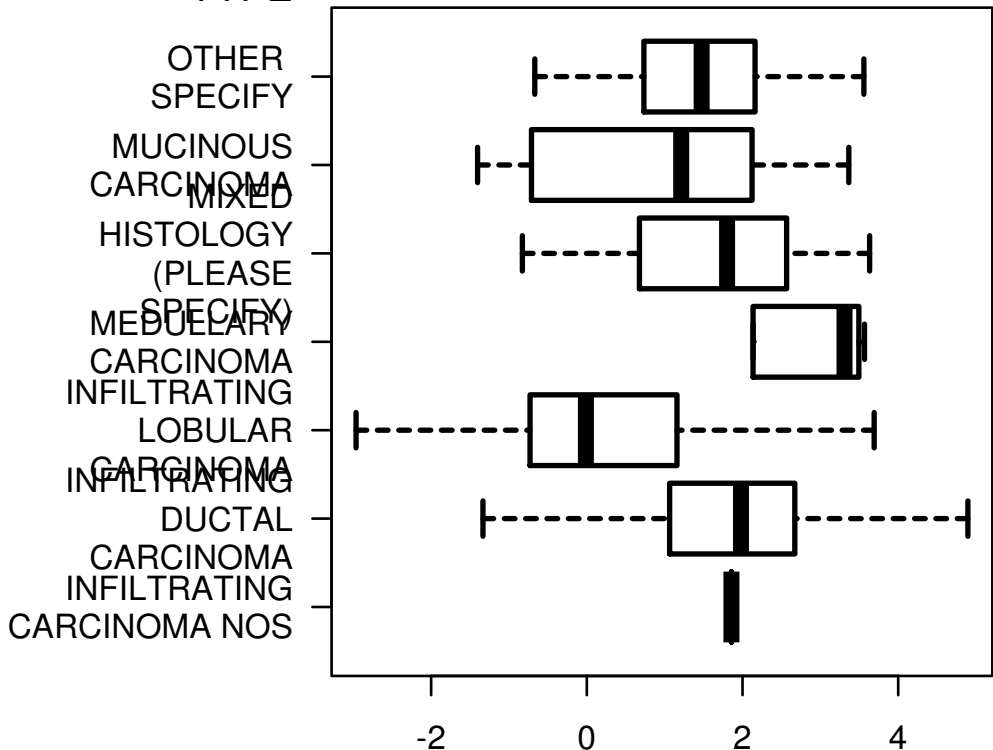


HISTOLOGICAL  
TYPE

# HSA-MIR-616



log2-EXPR

Kruskal-Wallis P = 5.56e-31