

# GPR109A|338442

HISTOLOGICAL  
TYPE

MUCINOUS  
ADENOCARCINOMA  
OF

ENDOCERVICAL  
ENDOMETRIUM

ADENOCARCINOMA  
OF ENDOCERVIX

ENDOCERVICAL  
TYPE OF

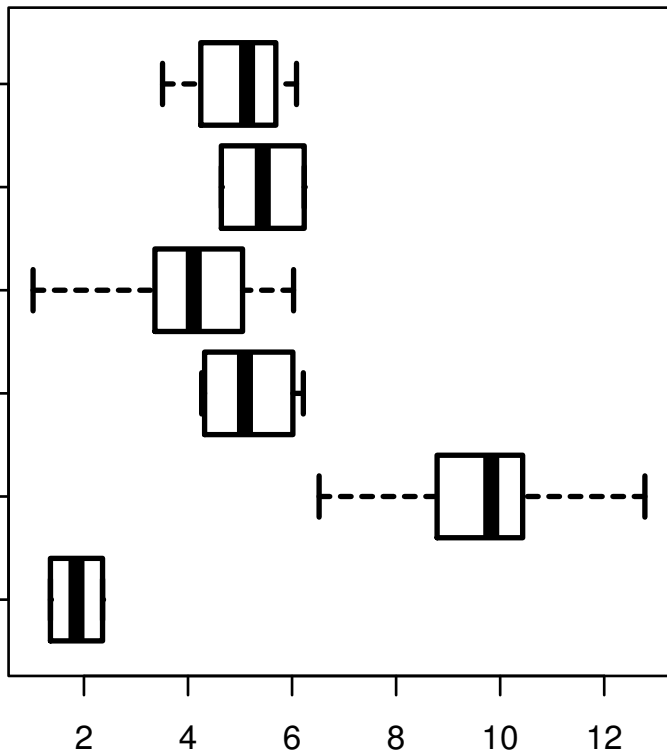
ADENOCARCINOMA  
ENDOCERVICAL

ADENOCARCINOMA  
OF THE USUAL

CERVICAL  
SQUAMOUS CELL

CARCINOMA

ADENOSQUAMOUS



log2-EXPR  
Kruskal-Wallis P = 4.05e-14