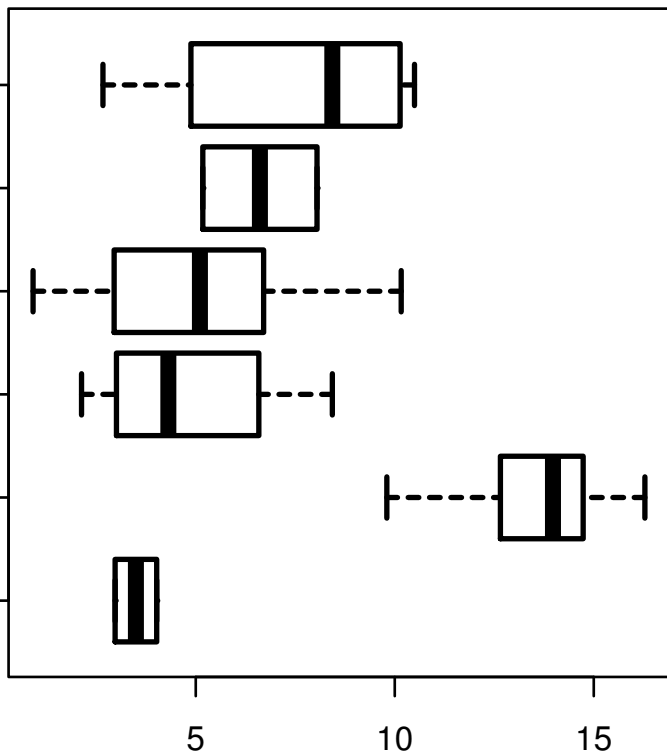


PKP1|5317

HISTOLOGICAL
TYPE
MUCINOUS
ADENOCARCINOMA
OF
ENDOCERVICAL
ENDOMETRIUM
TYPE
ADENOCARCINOMA
OF ENDOCERVIX
ENDOCERVICAL
TYPE OF
ADENOCARCINOMA
ENDOCERVICAL
ADENOCARCINOMA
OF THE USUAL
CERVICAL
TYPE
SQUAMOUS CELL
CARCINOMA
ADENOSQUAMOUS



log2-EXPR
Kruskal-Wallis P = 1.24e-13