

# DEPDC6|64798

HISTOLOGICAL

TYPE

MUCINOUS

ADENOCARCINOMA

OF

ENDOCERVICAL

ENDOMETRIUM

ADENOCARCINOMA

OF ENDOCERVIX

ENDOCERVICAL

TYPE OF

ADENOCARCINOMA

ENDOCERVICAL

ADENOCARCINOMA

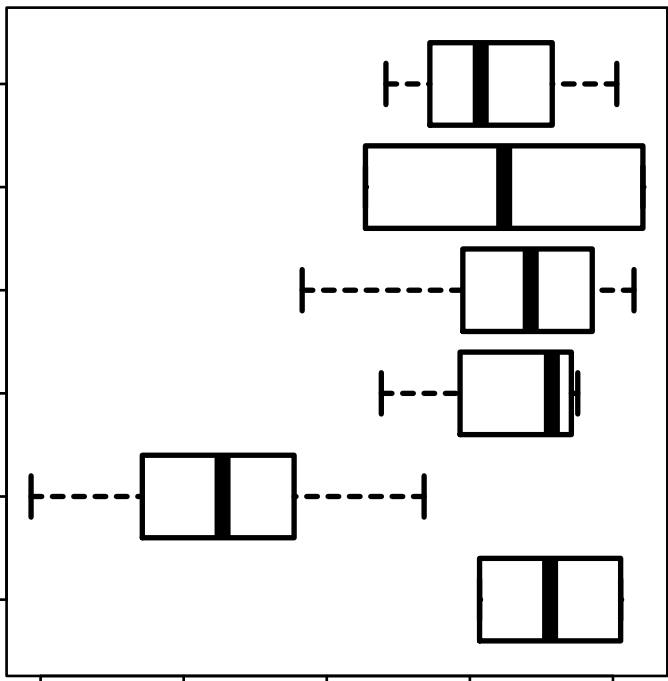
OF THE USUAL

CERVICAL

SQUAMOUS CELL

CARCINOMA

ADENOSQUAMOUS



log2-EXPR  
Kruskal-Wallis P = 4.08e-14