

# SLC19A3|80704

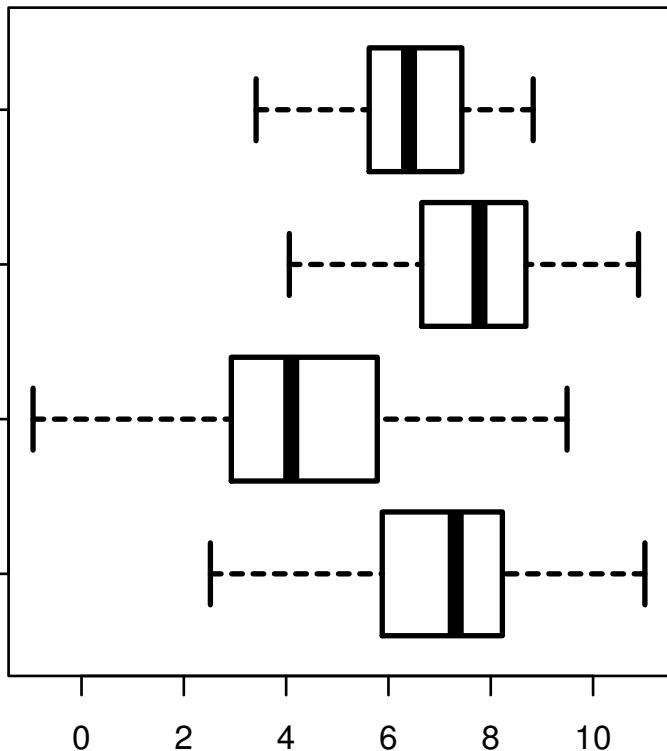
HISTOLOGICAL  
TYPE

RECTAL  
MUCINOUS  
ADENOCARCINOMA

RECTAL  
ADENOCARCINOMA

COLON  
MUCINOUS  
ADENOCARCINOMA

COLON  
ADENOCARCINOMA



log<sub>2</sub>-EXPR

Kruskal-Wallis P = 1.09e-17