

SMPD1

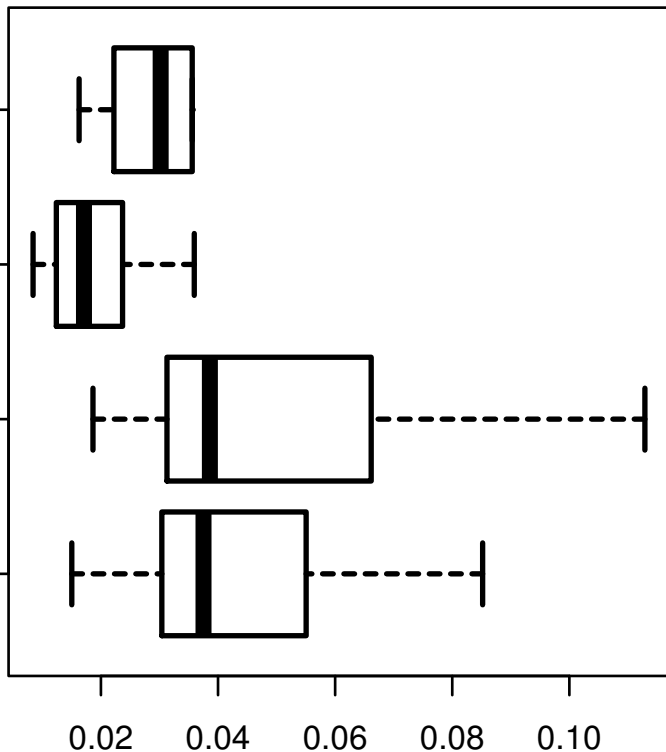
HISTOLOGICAL
TYPE

RECTAL
MUCINOUS
ADENOCARCINOMA

RECTAL
ADENOCARCINOMA

COLON
MUCINOUS
ADENOCARCINOMA

COLON
ADENOCARCINOMA



Kruskal-Wallis P = 3.8e-27

log2-EXPR