

# HSA-MIR-592

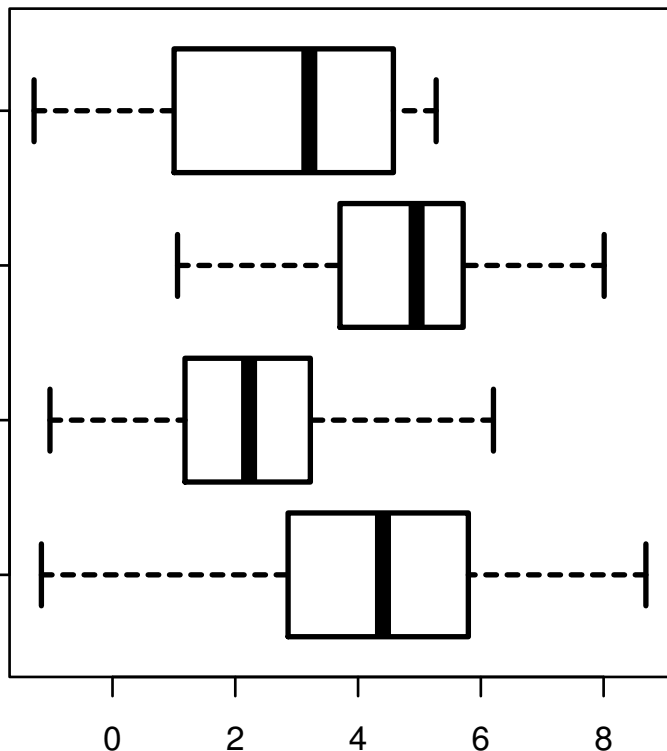
HISTOLOGICAL  
TYPE

RECTAL  
MUCINOUS  
ADENOCARCINOMA

RECTAL  
ADENOCARCINOMA

COLON  
MUCINOUS  
ADENOCARCINOMA

COLON  
ADENOCARCINOMA



log<sub>2</sub>-EXPR  
Kruskal-Wallis P = 6.32e-10