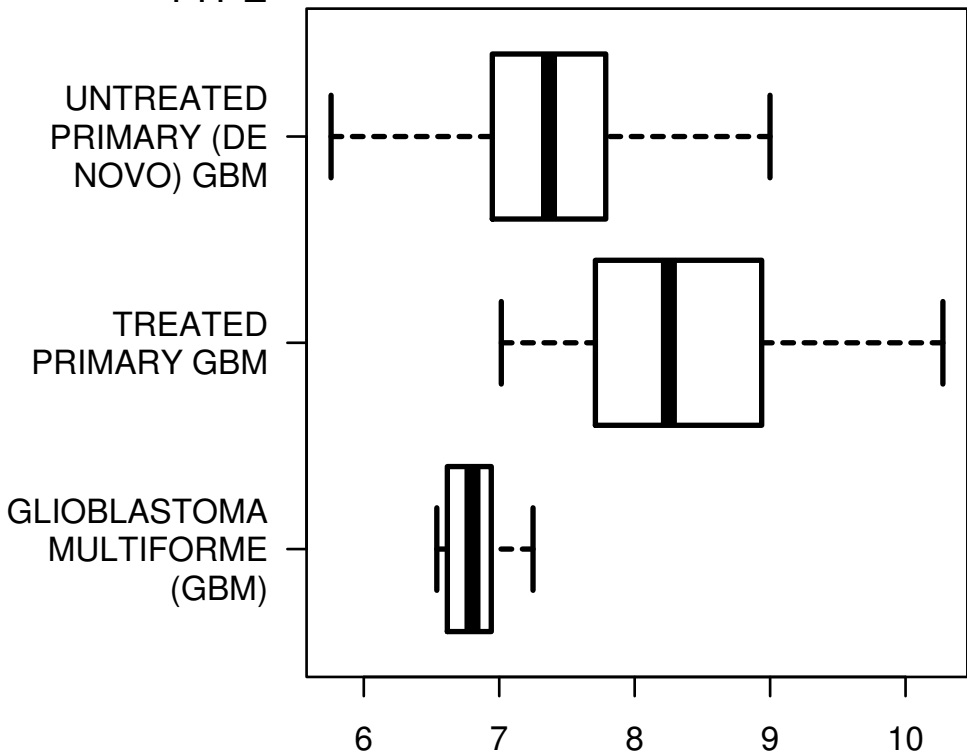


HISTOLOGICAL
TYPE

MRPS16



log₂-EXPR
Kruskal-Wallis P = 6.82e-07