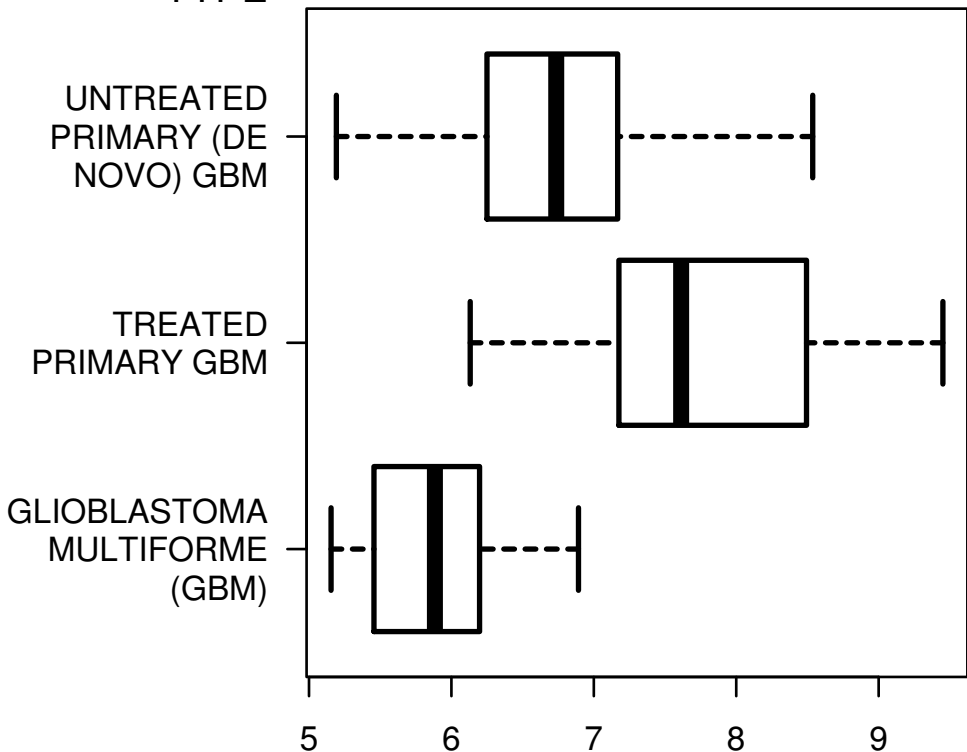


HISTOLOGICAL
TYPE

ALDH18A1



log2-EXPR
Kruskal-Wallis P = 1.72e-07