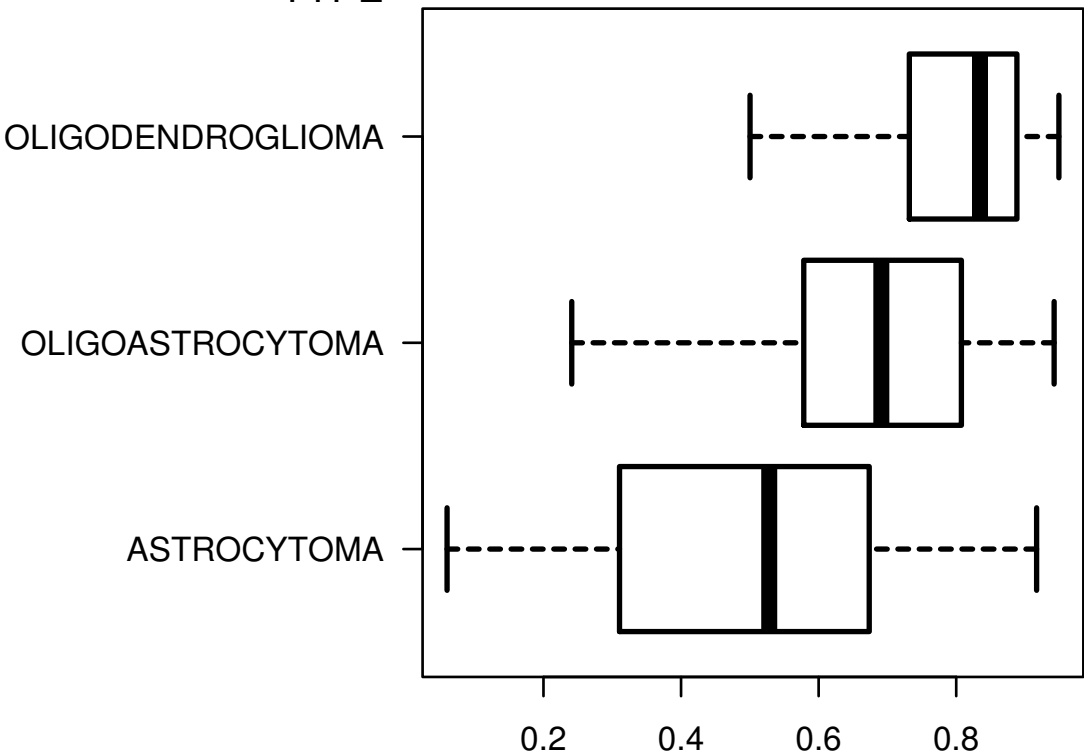


HISTOLOGICAL
TYPE

EMP1



log₂-EXPR

Kruskal-Wallis P = 3.09e-24