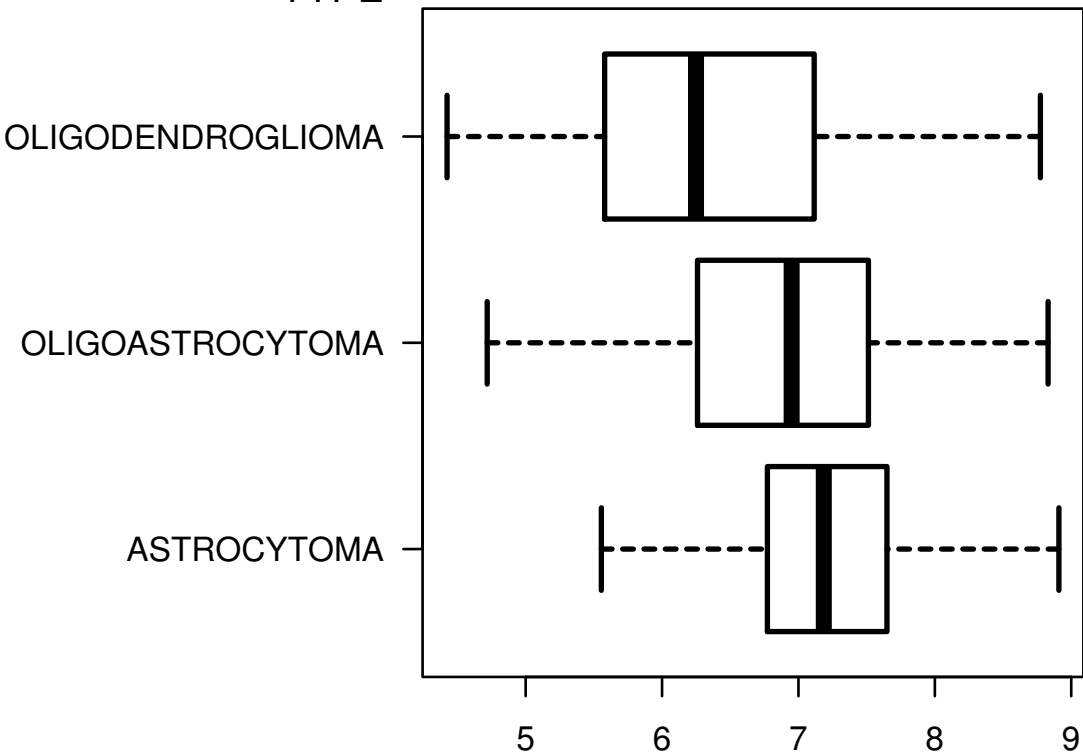


# HSA-MIR-186

HISTOLOGICAL  
TYPE



log2-EXPR  
Kruskal-Wallis P = 1.16e-13