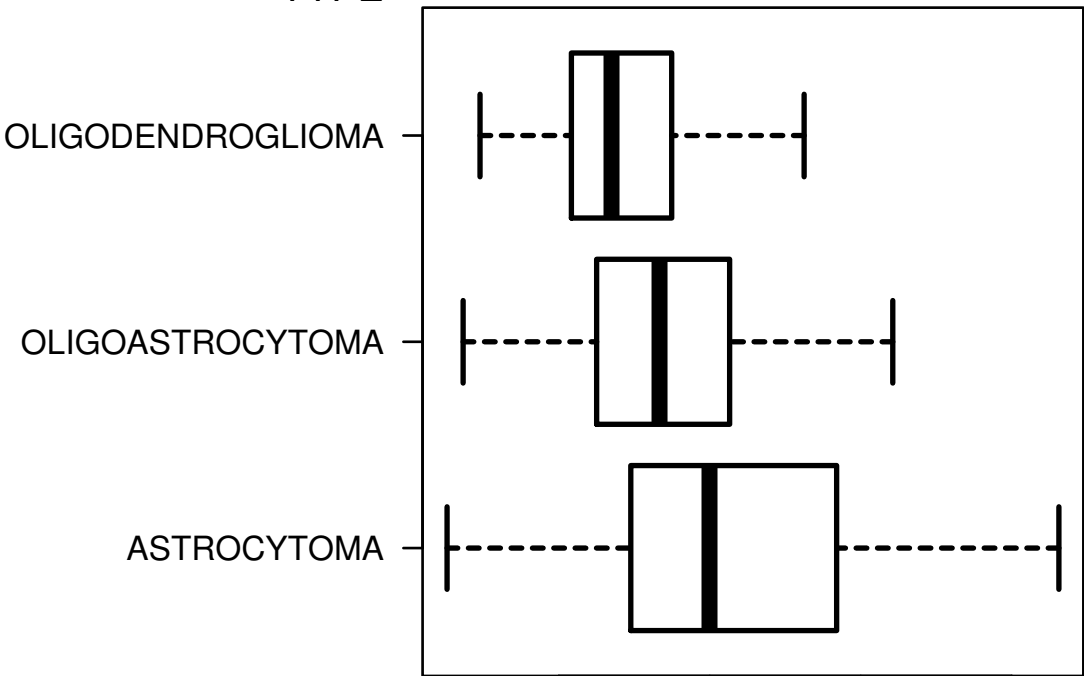


# HSA-MIR-21

HISTOLOGICAL  
TYPE



log2-EXPR  
Kruskal-Wallis P = 6.3e-11