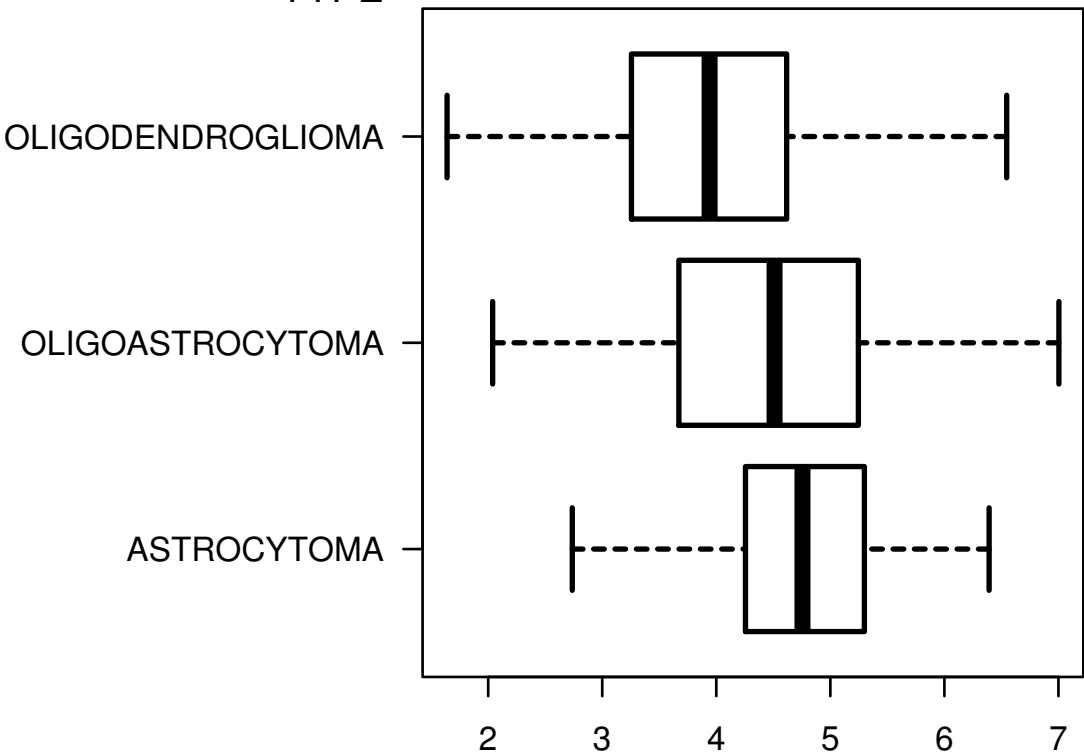


HSA-MIR-301A

HISTOLOGICAL
TYPE



log₂-EXPR
Kruskal-Wallis P = 7.47e-11