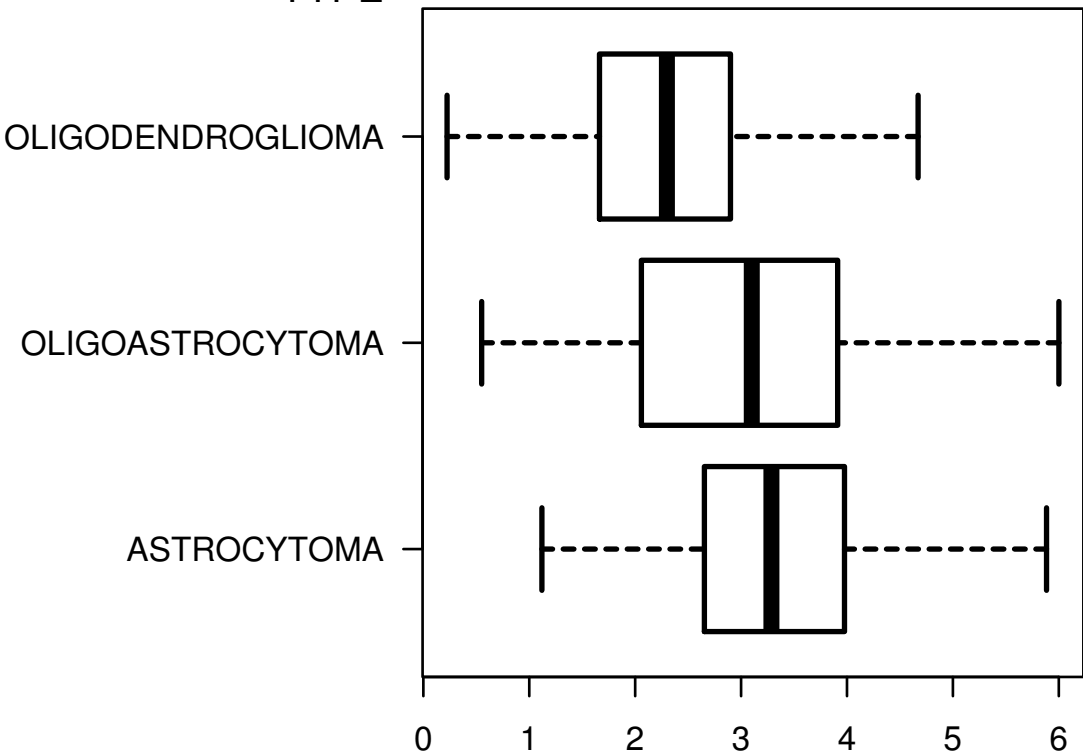


HSA-MIR-219-1

HISTOLOGICAL
TYPE



log₂-EXPR

Kruskal-Wallis P = 1.45e-12