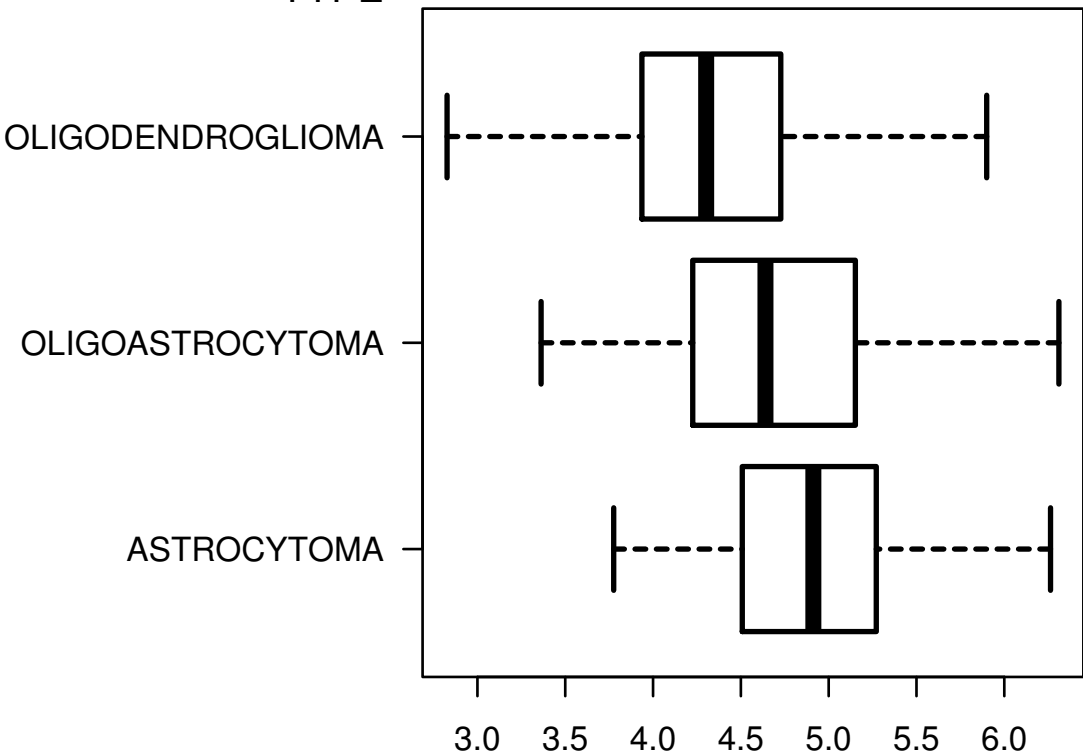


HSA-MIR-505

HISTOLOGICAL
TYPE



Kruskal-Wallis P = 6.83e-11