

NR3C2|4306

HISTOLOGICAL

TYPE

MUCINOUS

LUNG (SOLID)

CARCINOMA

PREDOMINANT

ADENOCARCINOMA

ADENOCARCINOMA

ADENOCARCINOMA

ADENOCARCINOMA

ADENOCARCINOMA

ADENOCARCINOMA

ADENOCARCINOMA

ADENOCARCINOMA

ADENOCARCINOMA

ADENOCARCINOMA

ADENOCARCINOMA

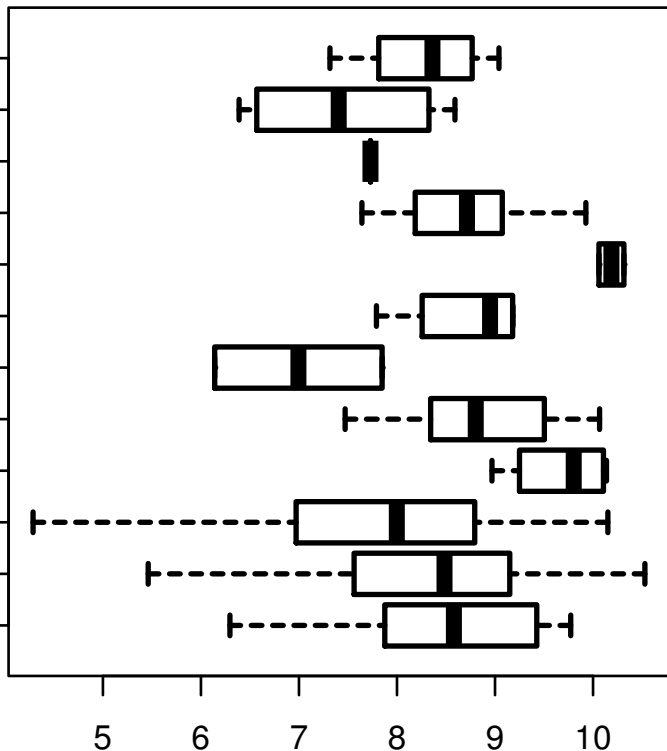
ADENOCARCINOMA

ADENOCARCINOMA

ADENOCARCINOMA

ADENOCARCINOMA

ADENOCARCINOMA



log2-EXPR

Kruskal-Wallis P = 4.65e-06