

UNC5CL|222643

HISTOLOGICAL

TYPE

THYROID

PAPILLARY

CARCINOMA -

TALL CELL (>=

50% TALL CELL

PAPILLARY

FEATURES)

FOLLICULAR

(>= 99%

FOLLICULAR

THYROID

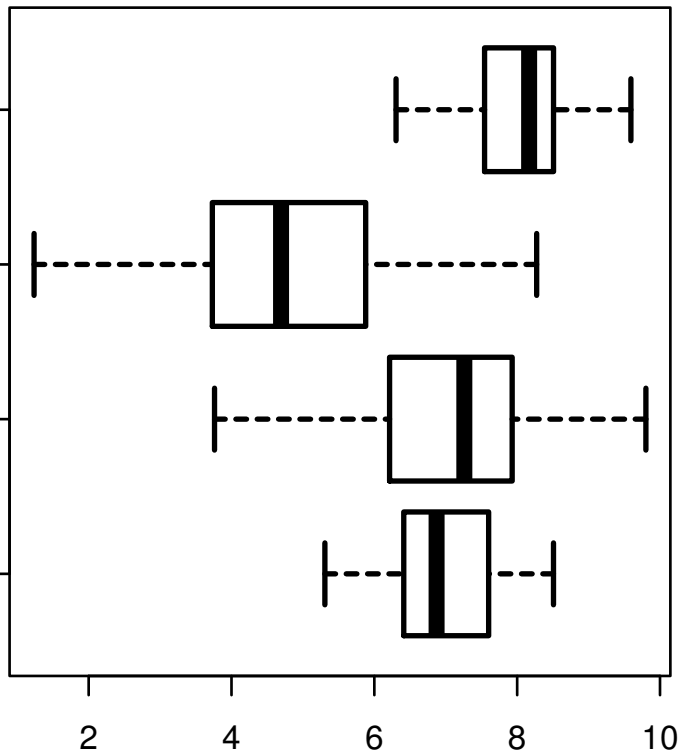
PATTERNED)

PAPILLARY

CARCINOMA -

OTHER

SPECIFY



log2-EXPR

Kruskal-Wallis P = 6.61e-32