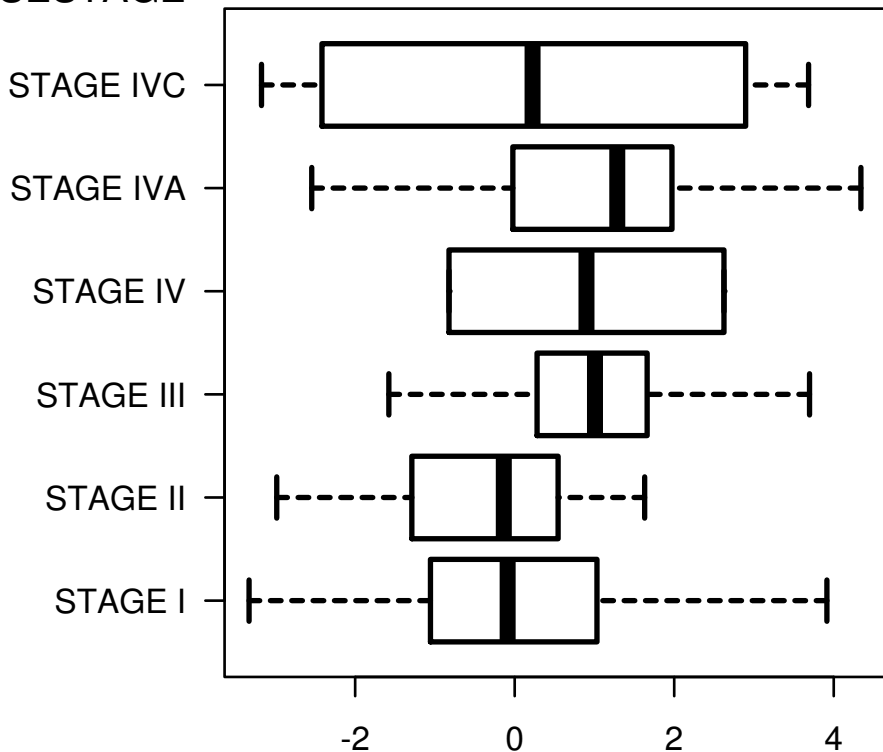


NEOPLASM  
DISEASESTAGE

# HSA-MIR-376C



Kruskal-Wallis P = 2.7e-07