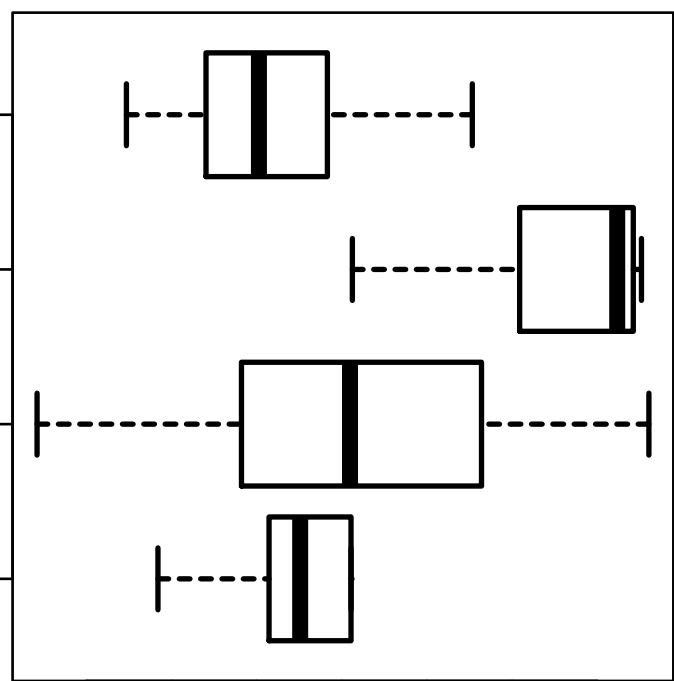


# FILIP1L\_\_1

HISTOLOGICAL  
TYPE  
THYROID  
PAPILLARY  
CARCINOMA -  
TALL CELL (>=  
50% TALL CELL  
PAPILLARY  
FEATURES)  
CARCINOMA -  
FOLLICULAR  
(>= 99%  
FOLLICULAR  
PATTERNED)  
THYROID  
PAPILLARY  
CARCINOMA -  
CLASSICAL/USUAL  
OTHER  
SPECIFY



log2-EXPR  
Kruskal-Wallis P = 8.29e-27