

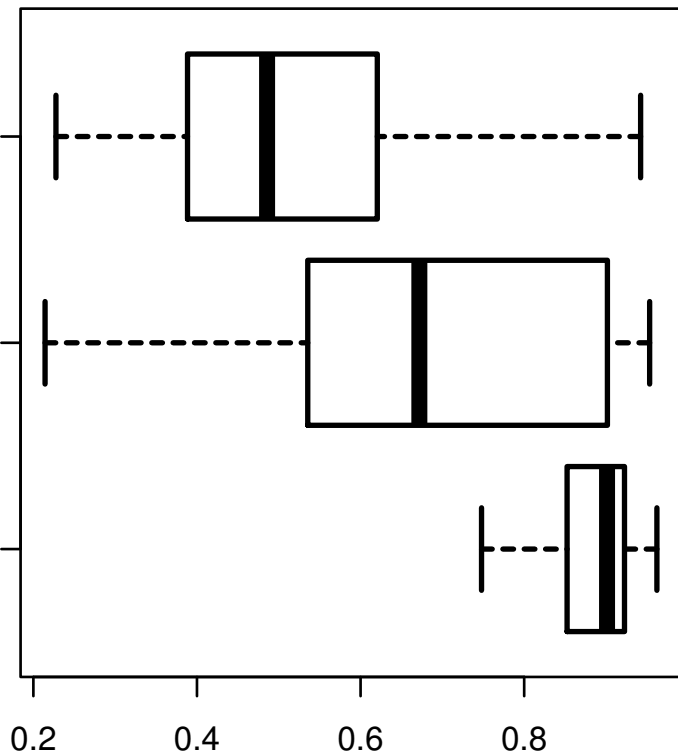
ITPK1

HISTOLOGICAL
TYPE

SEROUS
ENDOMETRIAL
ADENOCARCINOMA

MIXED SEROUS
AND
ENDOMETRIOID

ENDOMETRIOID
ENDOMETRIAL
ADENOCARCINOMA



log2-EXPR

Kruskal-Wallis P = 3.85e-29