

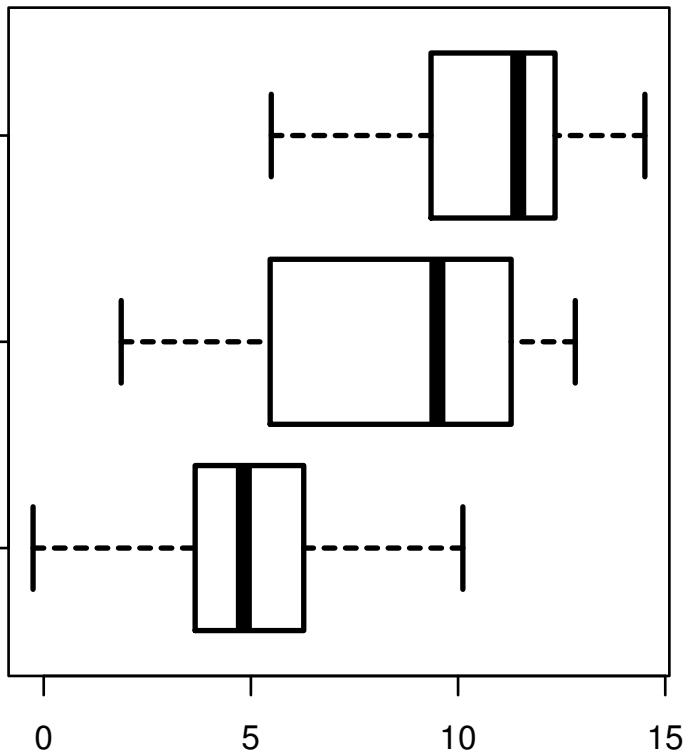
L1CAM|3897

HISTOLOGICAL
TYPE

SEROUS
ENDOMETRIAL
ADENOCARCINOMA

MIXED SEROUS
AND
ENDOMETRIOID

ENDOMETRIOID
ENDOMETRIAL
ADENOCARCINOMA



log2-EXPR
Kruskal-Wallis P = 4.38e-38