

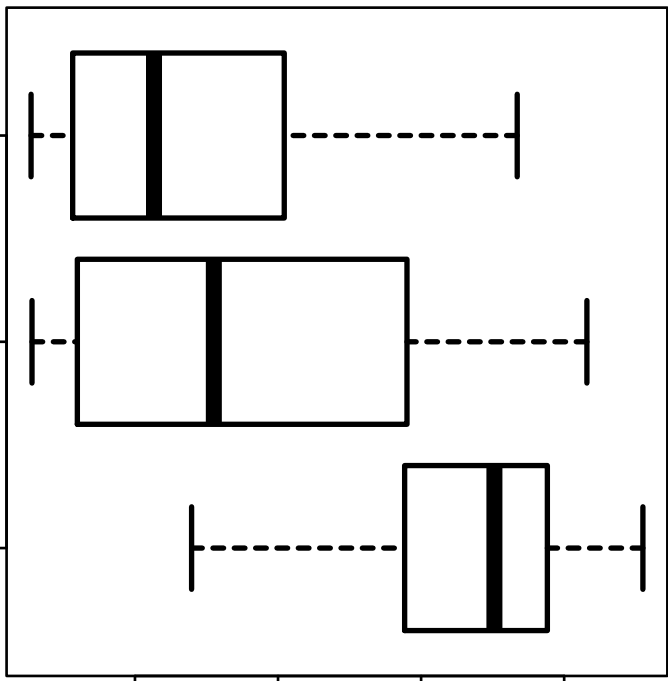
# APBB1IP

HISTOLOGICAL  
TYPE

SEROUS  
ENDOMETRIAL  
ADENOCARCINOMA

MIXED SEROUS  
AND  
ENDOMETRIOID

ENDOMETRIOID  
ENDOMETRIAL  
ADENOCARCINOMA



0.2 0.4 0.6 0.8

log2-EXPR

Kruskal-Wallis P = 5.86e-33