

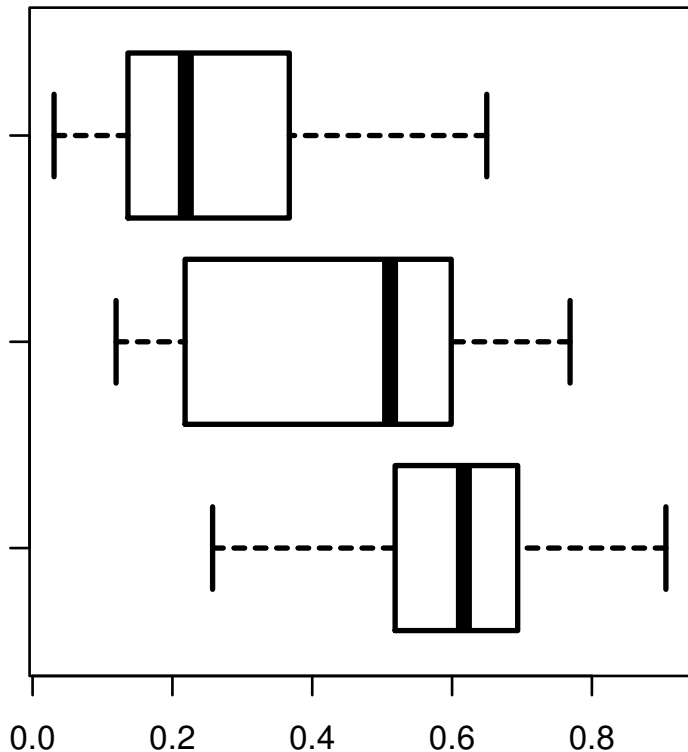
# ATP8A2

HISTOLOGICAL  
TYPE

SEROUS  
ENDOMETRIAL  
ADENOCARCINOMA

MIXED SEROUS  
AND  
ENDOMETRIOID

ENDOMETRIOID  
ENDOMETRIAL  
ADENOCARCINOMA



log<sub>2</sub>-EXPR  
Kruskal-Wallis P = 2.09e-28