

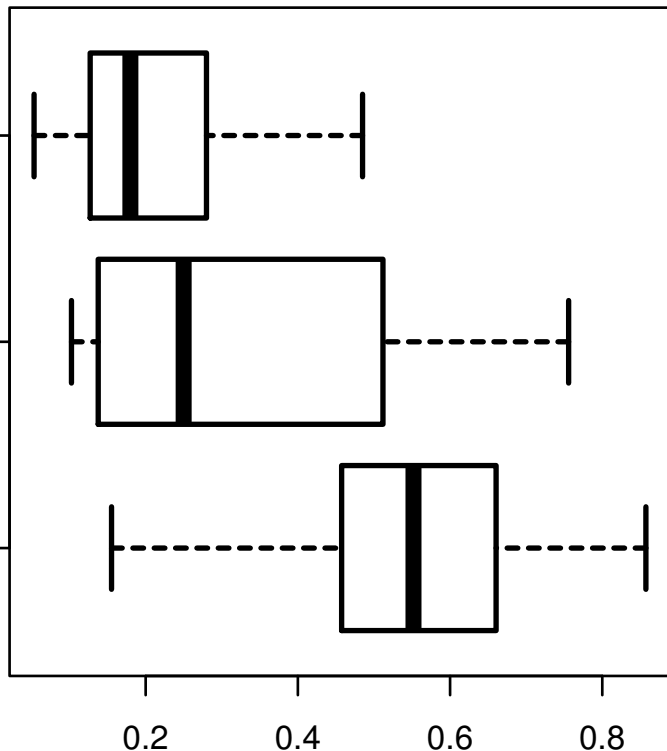
# KCNA5

HISTOLOGICAL  
TYPE

SEROUS  
ENDOMETRIAL  
ADENOCARCINOMA

MIXED SEROUS  
AND  
ENDOMETRIOID

ENDOMETRIOID  
ENDOMETRIAL  
ADENOCARCINOMA



log2-EXPR  
Kruskal-Wallis P = 1.21e-28