

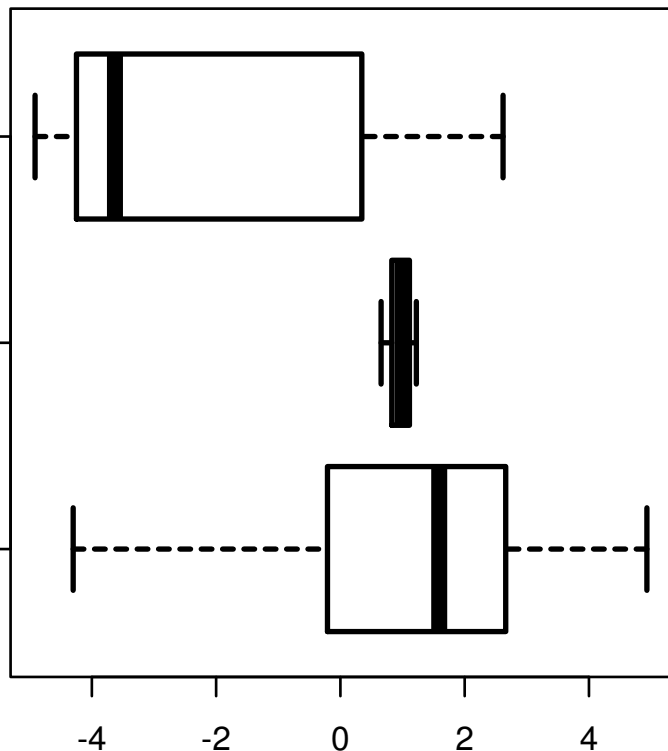
PGR|PR-R-V

HISTOLOGICAL
TYPE

SEROUS
ENDOMETRIAL
ADENOCARCINOMA

MIXED SEROUS
AND
ENDOMETRIOID

ENDOMETRIOID
ENDOMETRIAL
ADENOCARCINOMA



log2-EXPR
Kruskal-Wallis P = 2.88e-06