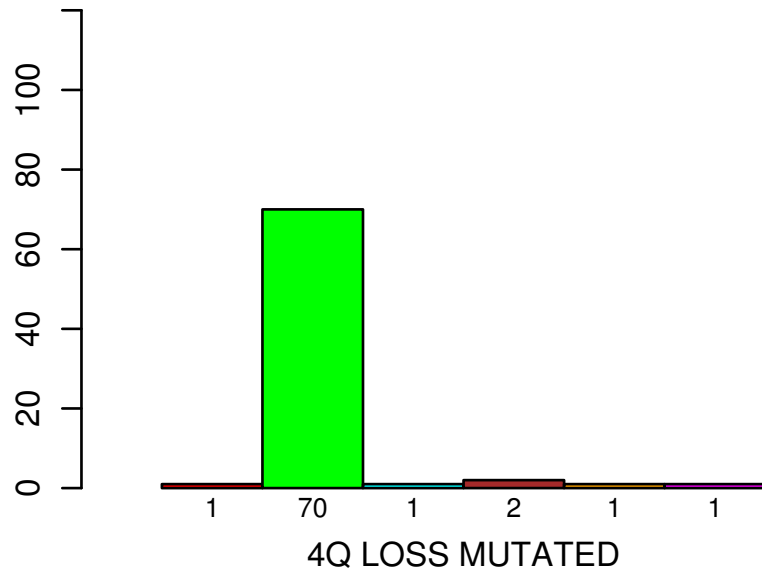
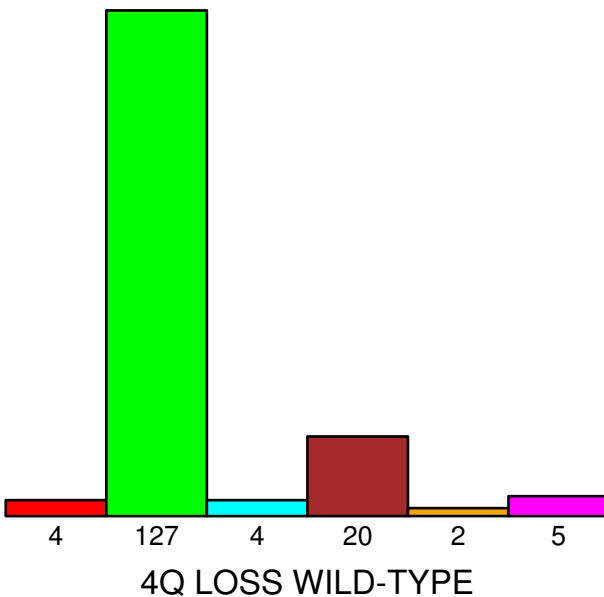


number of cases



HISTOLOGICAL TYPE



- ADENOSQUAMOUS
- CERVICAL SQUAMOUS CELL CARCINOMA
- ENDOCERVICAL ADENOCARCINOMA OF TH
- ENDOCERVICAL TYPE OF ADENOCARCINOMA
- ENDOMETRIOID ADENOCARCINOMA OF EN
- MUCINOUS ADENOCARCINOMA OF ENDOCI

Fisher's exact test $P = 0.118$