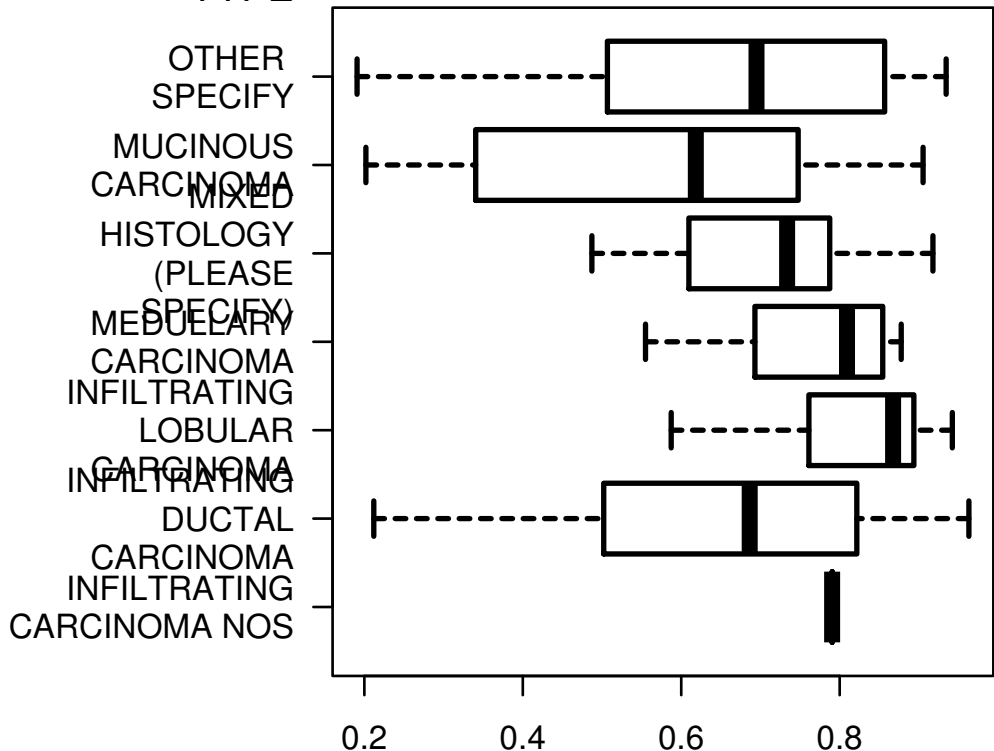


HISTOLOGICAL
TYPE

SCD



log2-EXPR
Kruskal-Wallis P = 4.17e-19