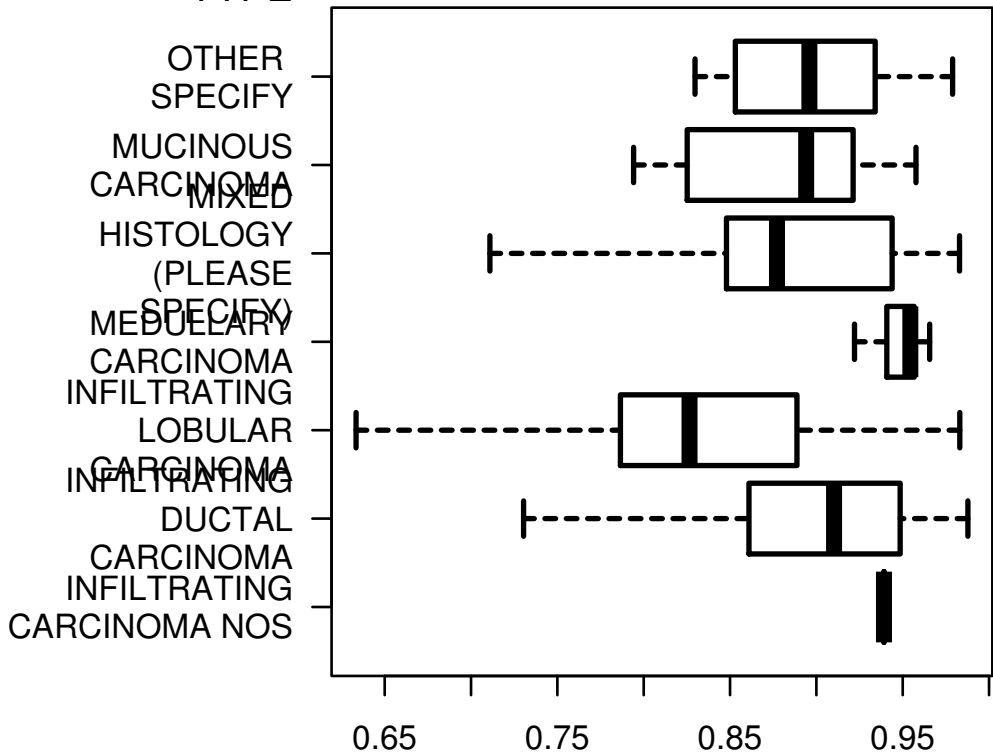


HISTOLOGICAL
TYPE

PRCD



log2-EXPR
Kruskal-Wallis P = 3.83e-18