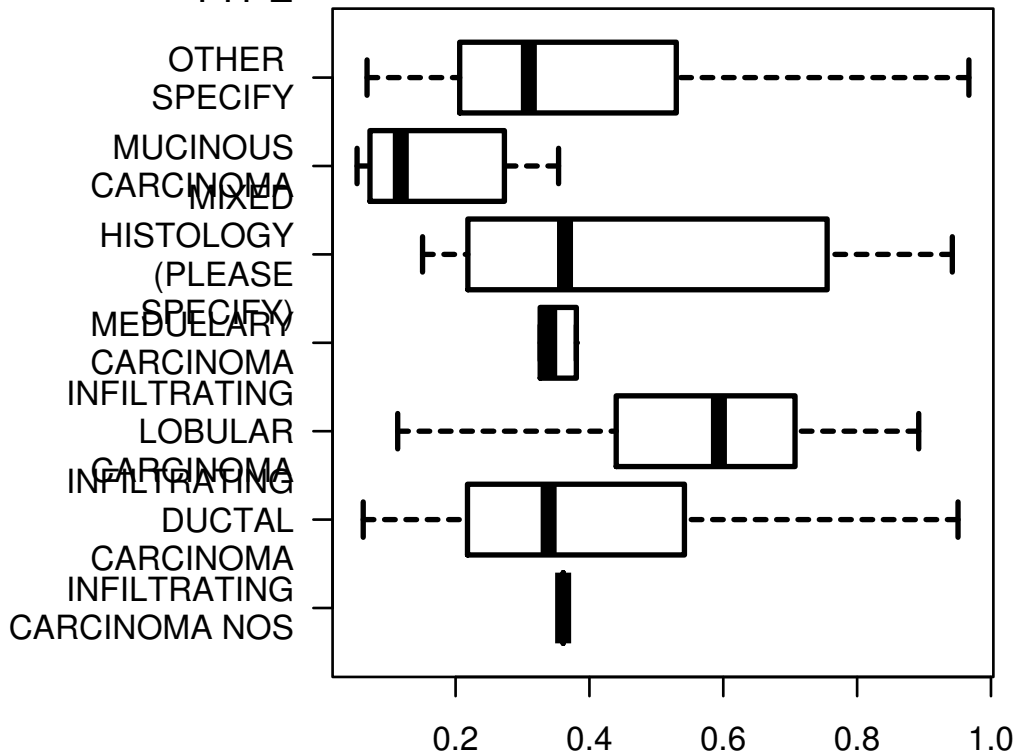


HISTOLOGICAL
TYPE

PELO_1



log2-EXPR
Kruskal-Wallis P = 3.01e-17