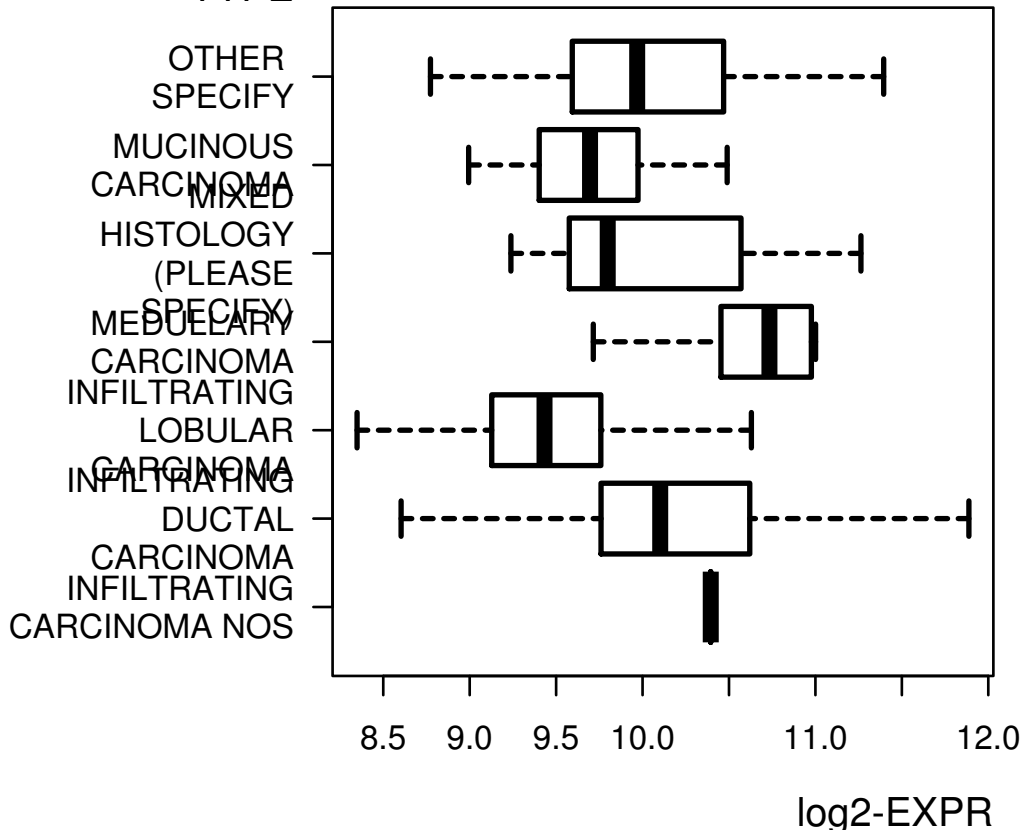


HISTOLOGICAL
TYPE

PSMD12|5718



Kruskal-Wallis P = 2.7e-38