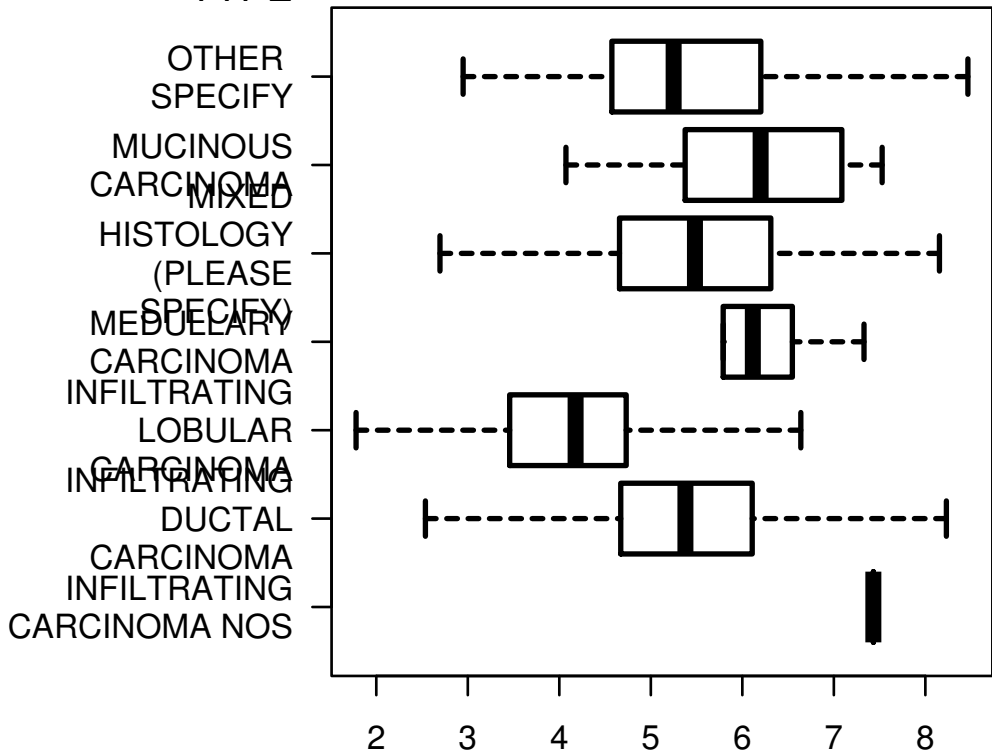


HSA-MIR-328

HISTOLOGICAL
TYPE



log2-EXPR

Kruskal-Wallis P = 2.45e-33