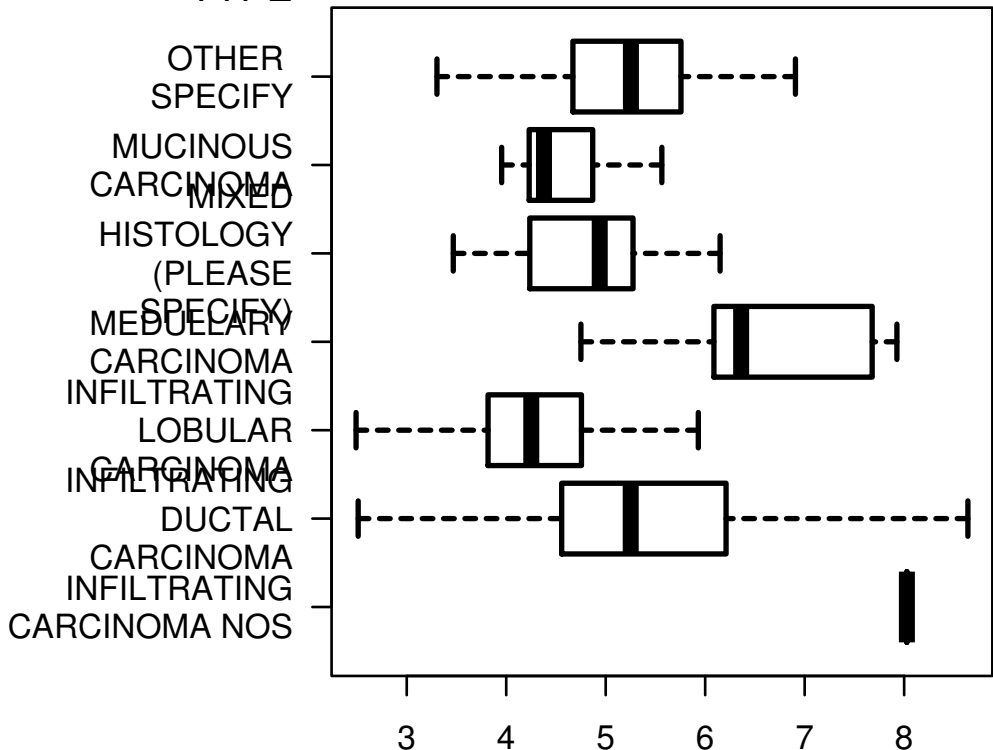


HISTOLOGICAL
TYPE

HSA-MIR-505



log2-EXPR
Kruskal-Wallis P = 3.3e-32