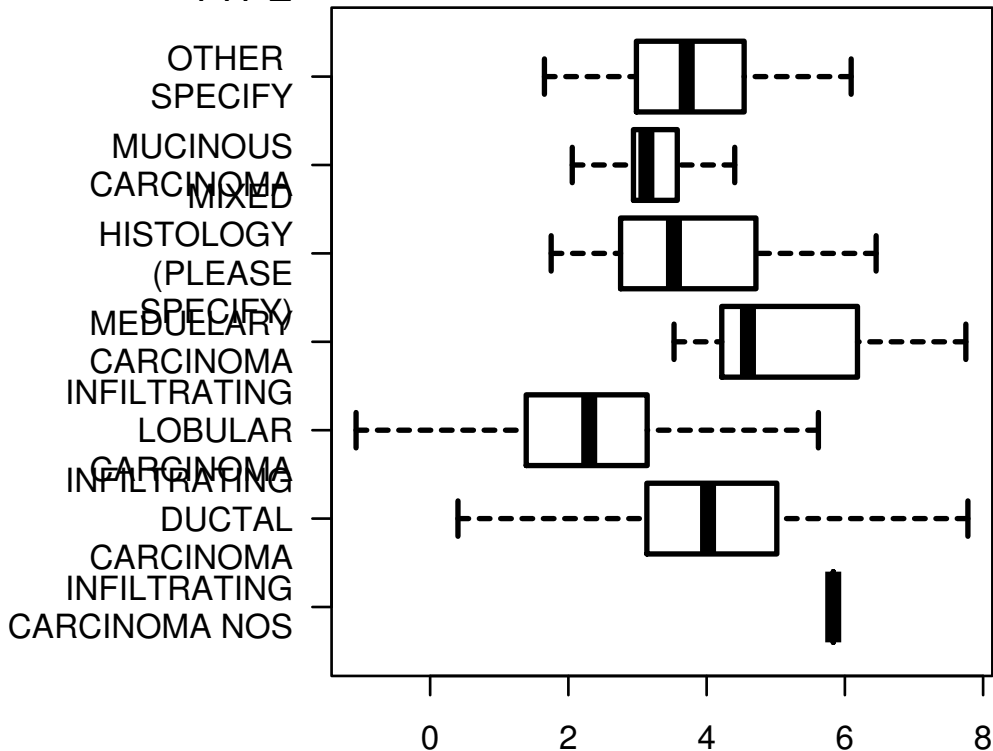


HISTOLOGICAL
TYPE

HSA-MIR-301A



log2-EXPR
Kruskal-Wallis P = 1.9e-34