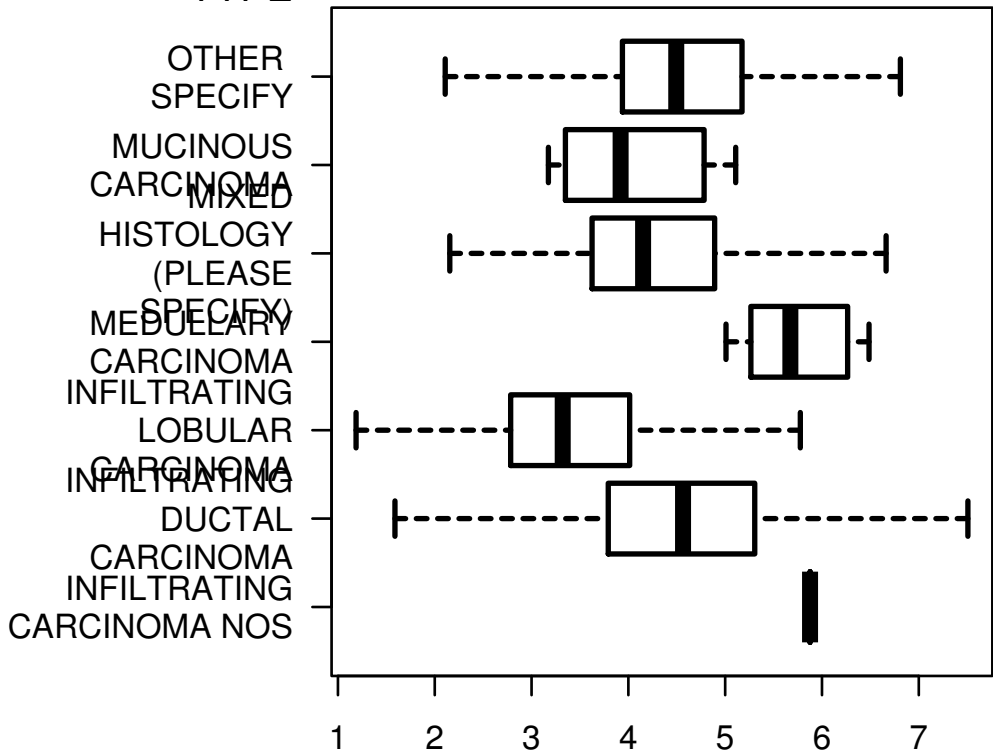


HISTOLOGICAL
TYPE

HSA-MIR-130B



log2-EXPR
Kruskal-Wallis P = 7.84e-34