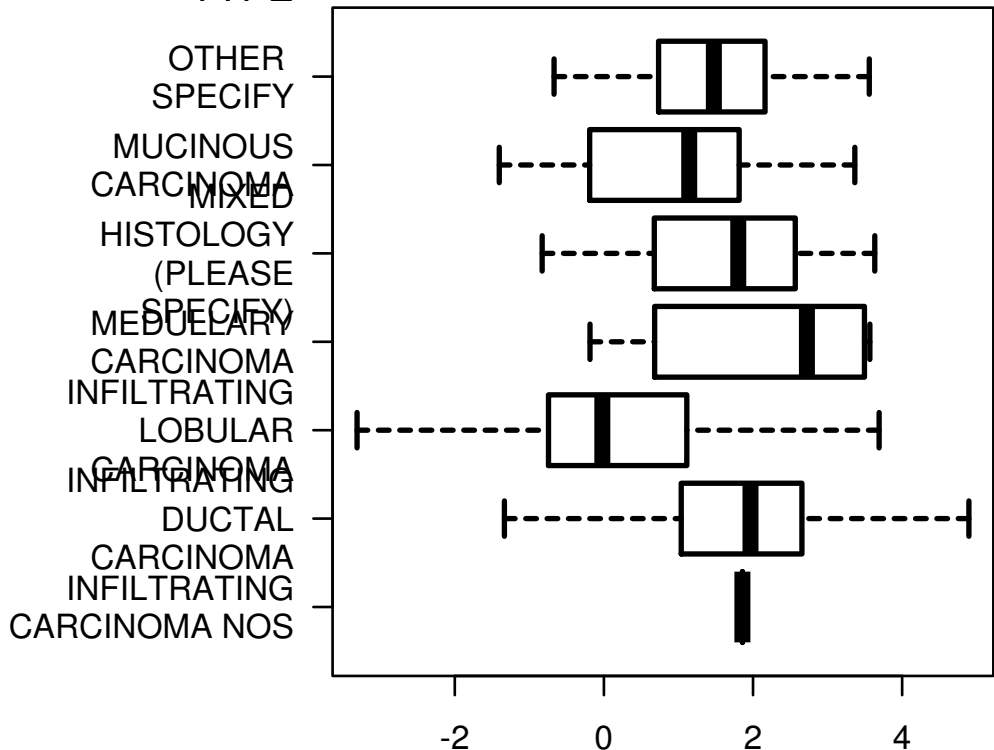


HISTOLOGICAL
TYPE

HSA-MIR-616



log2-EXPR
Kruskal-Wallis P = 2.5e-33