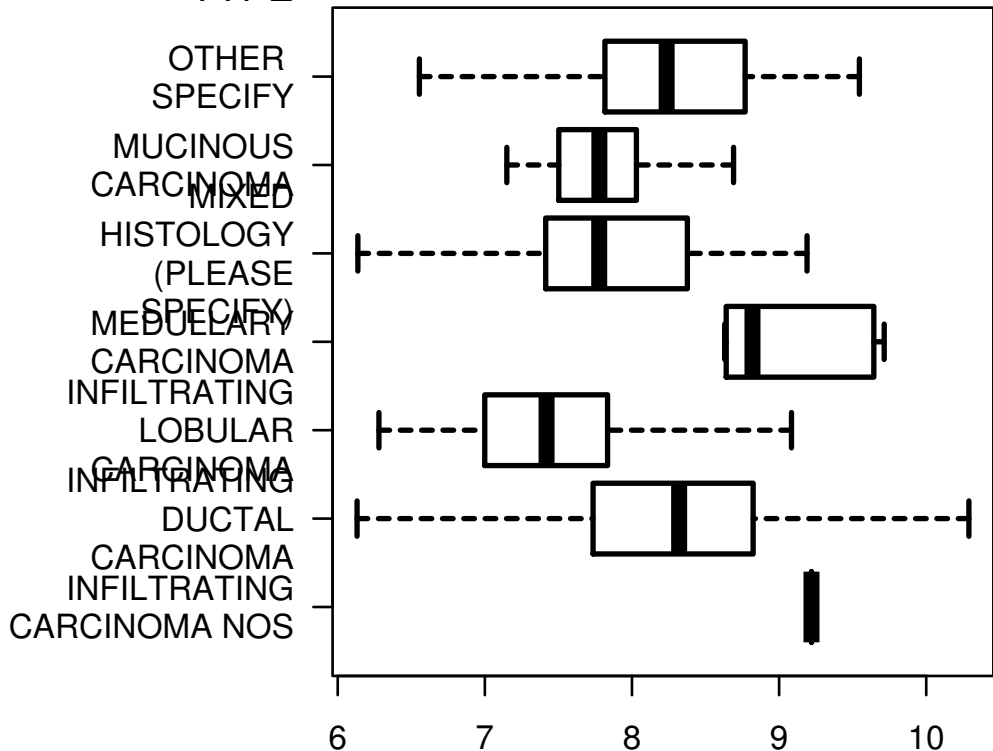


HSA-MIR-186

HISTOLOGICAL
TYPE



log2-EXPR
Kruskal-Wallis P = 1.63e-32