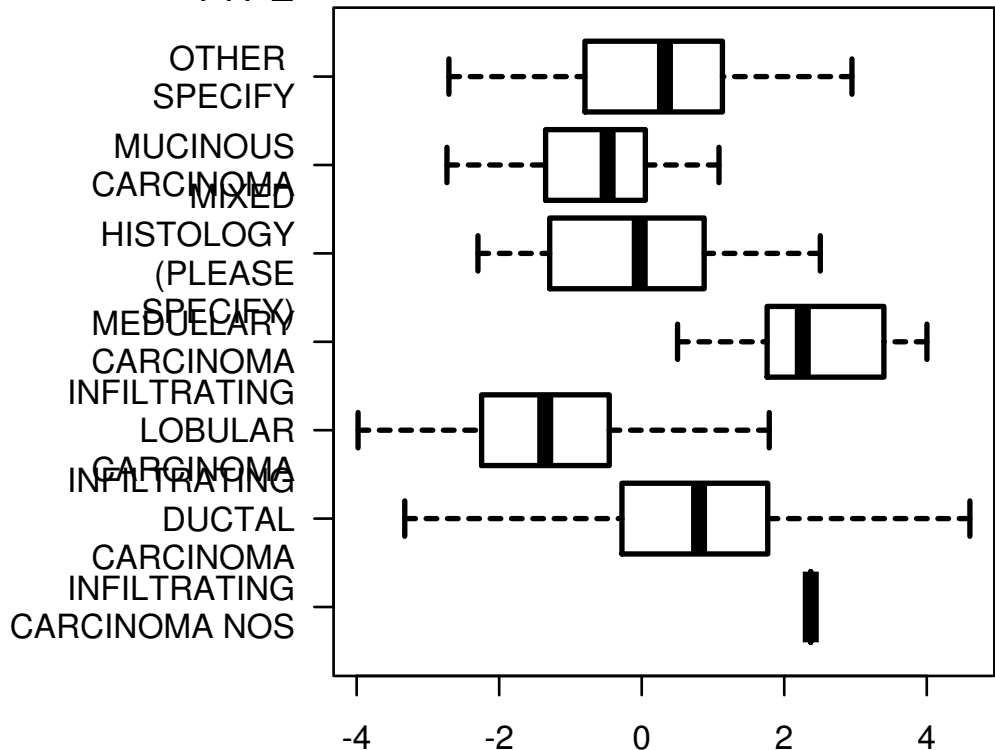


HISTOLOGICAL  
TYPE

# HSA-MIR-301B



log2-EXPR  
Kruskal-Wallis P = 1.63e-32